



European Training Curriculum for Radiology

Curriculum for the Level I
Training Programme (Years 1–3)

Curriculum for the Level II
Training Programme (Years 4–5)

As of late 2014, the ESR European Training Curriculum was officially supported by the following ESR Institutional Member Societies. All societies will be contacted again regarding the official support of the 2024 version.

NATIONAL SOCIETIES		SUBSPECIALTIES AND ALLIED SCIENCES SOCIETIES	
AUSTRIA	Austrian Roentgen Society	CIRSE	Cardiovascular and Interventional Radiological Society of Europe
BELARUS	Belarusian Society of Radiologists	ESCR	European Society of Cardiac Radiology
BELGIUM	Belgian Radiological Society	ESER	European Society of Emergency Radiology
BOSNIA AND HERZEGOVINA	Association of Radiology of Bosnia & Herzegovina	ESGAR	European Society of Gastrointestinal and Abdominal Radiology
BULGARIA	Bulgarian Association of Radiology	ESHNR	European Society of Head and Neck Radiology
CROATIA	Croatian Society of Radiology	ESMOFIR	European Society of Molecular and Functional Imaging in Radiology
CYPRUS	Cyprus Radiological Society	ESMRMB	European Society for Magnetic Resonance in Medicine and Biology
CZECH REPUBLIC	Czech Radiological Society	ESNR	European Society of Neuroradiology
DENMARK	Danish Society of Radiology	ESOI	European Society of Oncologic Imaging
ESTONIA	Estonian Society of Radiology	ESPR	European Society of Paediatric Radiology
FINLAND	Radiological Society of Finland	ESSR	European Society of Musculoskeletal Radiology
FRANCE	French Society of Radiology	ESTI	European Society of Thoracic Imaging
GEORGIA	Georgian Association of Radiologists	ESUR	European Society of Urogenital Radiology
GERMANY	German Radiological Society	EUSOBI	European Society of Breast Imaging
GREECE	Hellenic Radiological Society	EuSoMI	European Society of Medical Imaging Informatics
HUNGARY	Hungarian Society of Radiologists		
ICELAND	Radiological Society of Iceland		
IRELAND	Faculty of Radiologists, Royal College of Surgeons in Ireland		
ISRAEL	Israel Radiological Association		
ITALY	Italian Society of Radiology		
KAZAKHSTAN	Radiological Society of Kazakhstan		
LATVIA	Latvian Association of Radiologists		
LITHUANIA	Lithuanian Radiologists' Association		
MALTA	Maltese Association of Radiologists		
NETHERLANDS	Radiological Society of the Netherlands		
NORWAY	Norwegian Society of Radiology		
POLAND	Polish Medical Society of Radiology		
PORTUGAL	Portuguese Society of Radiology and Nuclear Medicine		
ROMANIA	Romanian Society of Radiology and Medical Imaging		
RUSSIA	Russian Association of Radiologists		
SERBIA	Radiological Society of Serbia		
SLOVAKIA	Slovak Radiological Society		
SLOVENIA	Slovenian Association of Radiology		
SPAIN	Spanish Society of Medical Radiology		
SWEDEN	Swedish Society of Medical Radiology		
SWITZERLAND	Swiss Society of Radiology		
TURKEY	Turkish Society of Radiology		
UKRAINE	Association of Radiologists of the Ukraine		

As of late 2014, the ESR European Training Curriculum was officially supported by the following ESR Associate Institutional Member Societies. All societies will be contacted again regarding the official support of the 2024 version.

NATIONAL SOCIETIES

ARGENTINA	Argentinian Society of Radiology
BOLIVIA	Bolivian Society of Radiology
BRAZIL	Brazilian College of Radiology
CHILE	Chilean Society of Radiology
CHINA	Chinese Society of Radiology
COLOMBIA	Colombian Association of Radiology
COSTA RICA	Costa Rican Association of Radiology
EGYPT	Egyptian Society of Radiology and Nuclear Medicine
HONDURAS	Honduran Society of Radiology
INDIA	Indian Radiological & Imaging Association
IRAN	Iranian Society of Radiology
IRAQ	Iraqi Association of Radiology
JAPAN	Japan Radiological Society
KOREA	Korean Society of Radiology
LEBANON	Lebanese Society of Radiology
MALAYSIA	Malaysian College of Radiology
MEXICO	Mexican Society of Radiology
MONGOLIA	Mongolian Radiological Society
PAKISTAN	Radiological Society of Pakistan
SAUDI ARABIA	Radiological Society of Saudi Arabia
SINGAPORE	Singapore Radiological Society
SOUTH AFRICA	Radiological Society of South Africa
SRI LANKA	Sri Lanka College of Radiologists
TUNISIA	Tunisian Society of Radiology
URUGUAY	Uruguayan Society of Radiology
UZBEKISTAN	Uzbekistan Radiology Society
VIETNAM	Vietnamese Society of Radiology and Nuclear Medicine
YEMEN	Yemen Society of Radiology

Endorsed by UEMS as UEMS 2018.37
European Training Requirements in Radiology
in Autumn 2018.

UEMS
(EUROPEAN UNION OF MEDICAL SPECIALISTS)



Adaptation to the UEMS format

Endorsed by the UEMS Radiology Section

Endorsed by the UEMS Council

Copyright notice

You may take temporary copies necessary to browse this website on screen. Universities and National Societies dedicated to the promotion of scientific and educational activities in the field of medical imaging are entitled to use the material as a guideline for educational purposes, but appropriate credit must be given to the ESR. Material must be reproduced as originally published and full credit must be given to the original publication.

This copyright notice must not be altered or removed. This material is for non-commercial use only, any commercial use of the material in whole or in part is strictly prohibited.

This work is licensed under a [Creative Commons Attribution-NonCommercial-ShareAlike 4.0 International License](https://creativecommons.org/licenses/by-nc-sa/4.0/).



EUROPEAN TRAINING CURRICULUM FOR RADIOLOGY

I.	TRAINING REQUIREMENTS FOR TRAINEES	Page 7
	Content of training and learning outcome	Page 7
B-I:	LEVEL I TRAINING PROGRAMME (YEARS 1-3)	Page 10
	B-I-1 Breast Radiology	Page 11
	B-I-2 Cardiac and Vascular Radiology	Page 13
	B-I-3 Chest Radiology	Page 16
	B-I-4 Emergency Radiology	Page 20
	B-I-5 Gastrointestinal and Abdominal Radiology	Page 23
	B-I-6 Gynaecological and Obstetric Radiology	Page 26
	B-I-7 Head and Neck Radiology	Page 28
	B-I-8 Interventional Radiology	Page 30
	B-I-9 Musculoskeletal Radiology	Page 32
	B-I-10 Neuroradiology	Page 34
	B-I-11 Paediatric Radiology	Page 37
	B-I-12 Urogenital Radiology	Page 40
	B-I-13 Nuclear Medicine as basic training	Page 42
	B-I-14 Radiation Protection Education and Training	Page 44
	B-I-15 Principles of Imaging Technology & Molecular Imaging	Page 48
	B-I-16 Principles of Medical Imaging Informatics	Page 53
	B-I-17 Communication and Management	Page 55
	B-I-18 Research and Evidence-Based Medicine	Page 57
B-II:	LEVEL II TRAINING PROGRAMME (YEARS 4-5)	Page 60
	B-II-1 Breast Radiology	Page 61
	B-II-2 Cardiac and Vascular Radiology	Page 65
	B-II-3 Chest Radiology	Page 70
	B-II-4 Emergency Radiology	Page 78
	B-II-5 Gastrointestinal and Abdominal Radiology	Page 84
	B-II-6 Gynaecological and Obstetric Radiology	Page 92
	B-II-7 Head and Neck Radiology	Page 96
	B-II-8 Interventional Radiology	Page 102
	B-II-9 Musculoskeletal Radiology	Page 108
	B-II-10 Neuroradiology	Page 114
	B-II-11 Oncologic Imaging	Page 123
	B-II-12 Paediatric Radiology	Page 127
	B-II-13 Urogenital Radiology	Page 134
	B-II-14 Medical Imaging Informatics	Page 138
	Organisation of Training	Page 141
	A. Schedule and Length of Training	Page 141
	B. Curriculum of Training / Infrastructural Aspects	Page 144
	C. Assessment and Evaluation	Page 148
	D. Governance	Page 149
	E. Entrustable Professional Activities	Page 150
II.	TRAINING REQUIREMENTS FOR TRAINERS	Page 162
	Process for recognition as trainer	Page 162
	Quality management for trainers	Page 162
III.	TRAINING REQUIREMENTS FOR TRAINING INSTITUTIONS	Page 163
	Process for recognition as training center	Page 163
	A. Requirements on staff and clinical activities	Page 163
	B. Requirements on equipment and accommodation	Page 164
	Quality management within training institutions	Page 165

PREFACE TO THE LEVEL I AND II

We are delighted to present the new edition of the ESR European Training Curriculum (ETC) Level I and II featuring meticulously revised content tailored for the radiological community.

The ETC outlines the training content and the expected learning outcomes of trainees in radiology. Its objective is to improve the quality of radiological care for patients across Europe through a standardised system of education.

As a living document, the ETC undergoes continuous refinement by the ESR Subspecialties and Allied Sciences Member Societies to align with the latest developments and knowledge in radiology. In line with this commitment, the 2024 edition introduces several pivotal updates.

The individual chapters' content has been thoughtfully refreshed by the respective ESR Subspecialties and Allied Sciences Societies, ensuring alignment with the most recent advancements in their respective sub-fields. Notably, this edition marks a significant milestone as, for the first time, The ESR European Training Curriculum Level I and II will include Entrustable Professional Activities (EPAs), a framework for assessing competence in a professional environment, influencing both residents and patients. The incorporation of EPAs into the ETC stands as a forward-looking decision, poised to significantly benefit the education and training of emerging European radiologists.

I would like to express my gratitude to the ESR Board of Directors and the ESR Executive Council as well as the ESR Subspecialties and Allied Sciences Member Societies and all individuals who played a role in enhancing this evolving document throughout the years.

Given the constant development of our specialty and the continuous technical advances, it is crucial to adapt the training model accordingly, and we are able to achieve this through the invaluable support of the European Society of Radiology.

Antwerp, March 2024

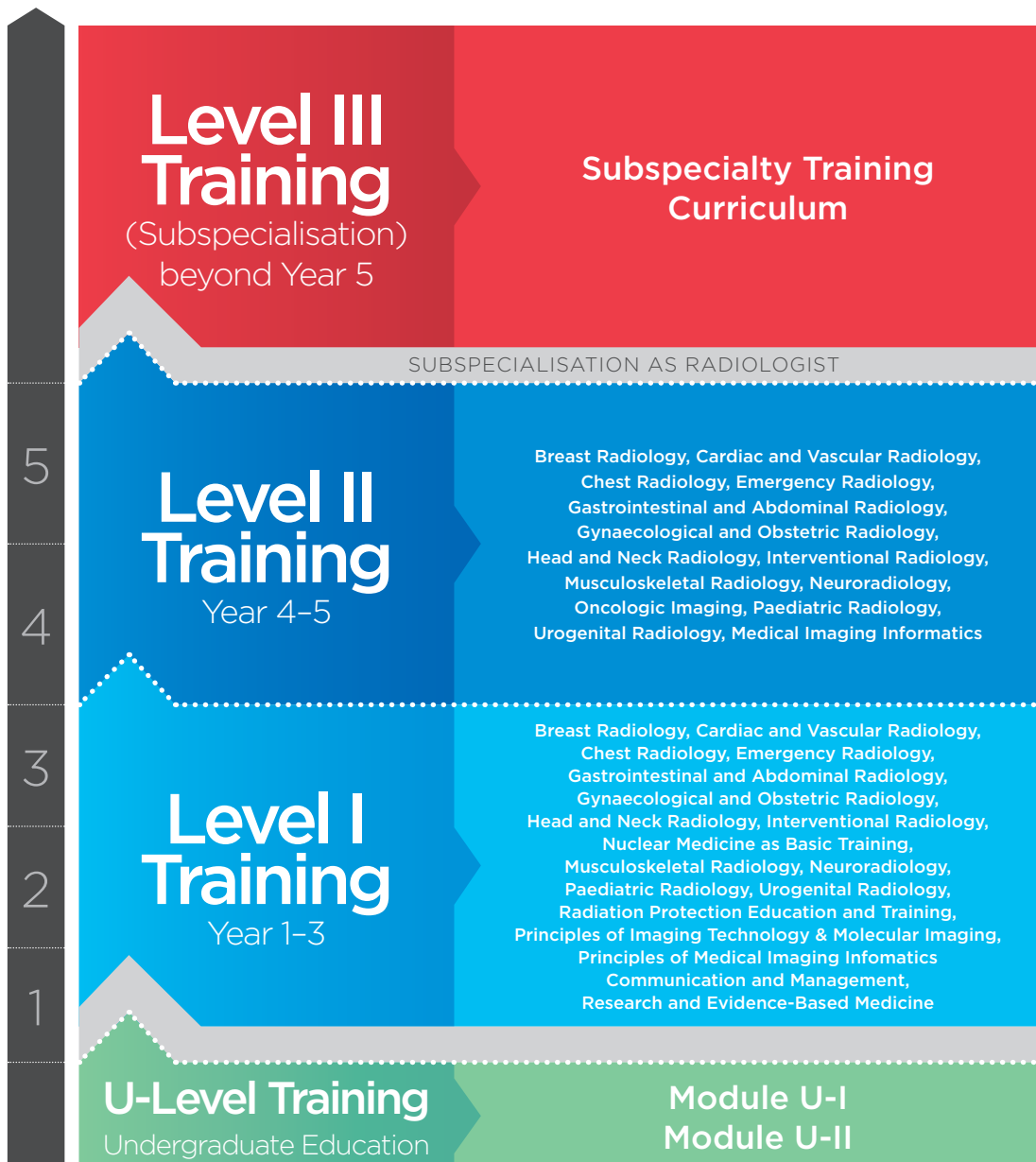Annemiek Snoeckx

Chairperson of the ESR Education Committee
(July 2023 – March 2025)

I. TRAINING REQUIREMENTS FOR TRAINEES

1. CONTENT OF TRAINING AND LEARNING OUTCOME

This chapter defines the contents of training and expected learning outcomes of trainees in radiology. Training shall be performed at several levels. The revised European Training Curriculum for Radiology continues to outline a five year (3 + 2) training period, consisting of Level I Training over the first three years followed by a more flexible Level II Training with potential special interest (elective) rotations during the last two years. Full subspecialty training with consecutive subspecialisation can be performed after this five-year training period, which corresponds to Level III training (not part of this curriculum). By general radiology, it is meant radiology training in all different subspecialties, without a specialised focus.



In international higher and post-graduate education there has been an increasing focus on competencies, rather than just education inputs. Instead of just focusing on the “learning inputs”, the “learning outputs” have increasingly been in the centre of educational attention and endeavours. This led to concepts of Knowledge, Skills and Competences (KSCs) or of Knowledge, Skills and Attitudes (KSAs). These learning outcomes are less dependent on the times and routes of acquisition.

While the concept of “knowledge” has been the traditional basis for educational curricula providing lists of topics the trainee is expected to learn, the concepts of skills, competences and attitudes are more difficult to appreciate. The word “skill” is usually applied to describe a level of performing a particular task – this can be a motor task (e.g. performing an arterial puncture) or a cognitive task. The term “competences” has been subject to frequent debates in the past years with several different models being in use.

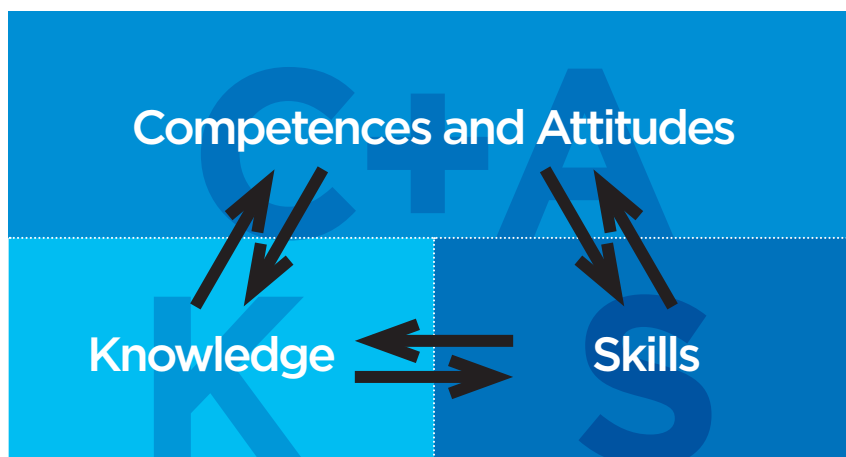
Competences tend to develop from an initially rule-based, inflexible behaviour to an intuitive understanding of the situation and comprehension of the crucial aspects of a situation. This development should be encouraged throughout the training.

The following training curriculum / syllabus is divided into two levels of training (Level I and Level II) and further subdivided into the different areas of training. These chapters are further divided into the following sections:

Knowledge: this section includes the main domains of theoretical knowledge the trainee should master in this specialty area

Skills: this section includes the key practical and clinical skills the trainee should acquire in this specialty area

Competences and attitudes: this section includes the competences to be mastered as well as the domains of professionalism the trainee should acquire in this specialty area



The European Board of Radiology (EBR) has prepared a tool in order to test the fundamentals of General Radiology. It is a self-assessment test that includes 100 Multiple Response Questions (MRQs) and 10 Short Cases (SCs) and it is based on Level I of the ETC.

You can access a free version of this resource using the following links:

- Check the 100 MRQs here <https://edir.myebr.org/public/sample/?id=2956>
- Check the 10 SCs here <https://edir.myebr.org/public/sample/?id=2957>

B-I:
**LEVEL I
TRAINING
(YEARS 1-3)**

LEVEL I TRAINING (YEARS 1-3)

The subject content of the curriculum for Level I Training includes the following elements:

B-I-1 Breast Radiology

B-I-2 Cardiac and Vascular Radiology

B-I-3 Chest Radiology

B-I-4 Emergency Radiology

B-I-5 Gastrointestinal and Abdominal Radiology

B-I-6 Gynaecological and Obstetric Radiology

B-I-7 Head and Neck Radiology

B-I-8 Interventional Radiology

B-I-9 Musculoskeletal Radiology

B-I-10 Neuroradiology

B-I-11 Paediatric Radiology

B-I-12 Urogenital Radiology

B-I-13 Nuclear medicine as basic training

B-I-14 Radiation Protection Education and Training

B-I-15 Principles of Imaging Technology & Molecular Imaging

B-I-16 Principles of Medical Imaging Informatics

B-I-17 Communication and Management

B-I-18 Research and Evidence-Based Medicine

B-I-1 BREAST RADIOLOGY

Content reviewed by EUSOBI (European Society of Breast Imaging)

INTRODUCTION

The aim of this curriculum in breast imaging is to ensure that the trainee develops core knowledge of imaging normal breast and breast diseases that will form the basis for further training (if desired). It will also provide transferable skills that will equip the trainee to work as a specialist in any branch of radiology.

Physics and radiation protection are covered in separate courses and are not covered in detail unless specific to breast imaging.

KNOWLEDGE

- To understand the anatomy and physiology of the female breast and how it changes with age
- To understand the anatomy of the axilla
- To describe normal variants and abnormalities of the female breast
- To have an understanding of clinical practice relevant to breast imaging
- To describe the standard views of digital mammography (mediolateral oblique and craniocaudal) and additional views and their uses (mediolateral, extended craniocaudal, lateral, magnification views)
- To be aware of tomosynthesis and contrast enhanced mammography
- To understand physics in mammography, particularly regarding image acquisition and how this may affect image quality
- To explain principles of current practice in breast cancer screening
- To understand the risk/benefit analysis associated with breast cancer screening
- To describe the application of other imaging techniques in breast imaging, such as ultrasound and MRI and to put these into a correct diagnostic pathway
- To describe the indications and contraindications for image-guided (ultrasound, mammography and MRI) interventional breast procedures (fine needle aspiration, core needle biopsy, vacuum-assisted biopsy, presurgical localisation techniques)
- To distinguish the appearance of common benign and malignant diseases of the breast on mammography, ultrasound, and MRI
- To understand principles and basic application of standardised diagnostic categorisation systems such as the ACR Breast Imaging Reporting and Data System (BI-RADS®) with reference to mammography, ultrasound and MRI
- To describe the principles of communication specifically related to the breaking of bad news and consent
- To understand the impact of radiological diagnosis on the treatment (breast conserving/mastectomy)
- To understand the presence of pathological lymph nodes and the significance for further procedures (sentinel/lymphadenectomy)

SKILLS

- To perform ultrasound examinations of the breast and axilla under supervision
- To perform interventional breast procedures under ultrasound and X-ray guidance under supervision

COMPETENCES AND ATTITUDES

- To justify diagnostic imaging examinations of the breast
- To choose the best-suited method for evaluating disorders of the breast or for specific clinical problems
- To communicate with the patient in order to obtain informed consent prior to interventional procedures of the breast
- To choose optimal imaging parameters for mammography
- To apply techniques to reduce exposure doses of mammography
- To supervise and teach technical staff to ensure that appropriate images are obtained
- To report mammography, breast ultrasound, and breast MRI with respect to common breast diseases, using descriptors and diagnostic categories according standardised systems such as BI-RADS®
- To appreciate own limitations and to identify when it is appropriate to obtain assistance in interpreting and reporting breast images
- To communicate with patients and their relatives in order to explain the nature of benign breast disease
- To observe bad news being given to patients and their relatives
- To communicate with patients and their relatives to give bad news
- To participate in and to perform under supervision at multi-disciplinary breast conferences and tumour boards

B-I-2 CARDIAC AND VASCULAR RADIOLOGY

Content reviewed by ESCR (European Society of Cardiovascular Radiology)

INTRODUCTION

The aim of this curriculum in cardiovascular imaging is to ensure that the trainee develops core knowledge of the relative value of available imaging modalities with regard to normal heart and great vessels. This includes an understanding of basic cardiac physiology and common normal variants. This knowledge will form the basis for further training (if desired) and also provide transferable skills that will equip the trainee to work as a specialist in any branch of radiology as well as for managing the emergency cardiovascular patient.

Physics, contrast media and radiation protection are covered in separate sections, and therefore are not included in detail in this section, unless of particular relevance to cardiovascular imaging.

KNOWLEDGE

- To describe the normal anatomy of the heart and vessels including the lymphatic system as demonstrated by radiographs, CT and MRI
- To analyse a chest X-ray and recognise normal as well as abnormal cardiovascular structures and related pathology
- To describe the major coronary anatomy using CT
- To know how to use beta-blockers and nitroglycerin before coronary CTA
- To describe normal variants of the cardiac, vascular and lymphatic systems
- To understand the mean exposure doses of radiographs and CT examinations of the cardiac and vascular systems, as well as strategies to reduce the radiation dose
- To describe the principles of digital imaging and image processing pertinent to radiology of the cardiac and vascular systems
- To describe the basic technique of cardiovascular CT, including ECG-gating techniques and contrast media injection parameters
- To know about routinely used cardiovascular MRI sequences and cardiac imaging planes
- To understand the cardiac physiology in the healthy heart and in those with cardiopulmonary disease
- To know the differential diagnosis of the acute and chronic chest pain
- To understand indications and contraindications for cardiovascular CT and MRI
- To understand the general principles and classification of congenital heart disease and the diagnostic features on conventional radiographs
- To differentiate radiological features and causes of cardiac chamber dilatation and/or hypertrophy, including acquired valvular disease, and pulmonary vascular disease

- To analyse and explain the diagnostic evaluation of ischaemic heart disease, including cardiac coronary CTA and cardiac MRI (infarction/viability assessment)
- To understand the basics of radionuclide imaging and coronary arteriography in coronary artery disease
- To identify MRI features of acute myocarditis
- To know typical morphological changes in patients with cardiovascular trauma
- To identify the typical feature of arterial stenosis, occlusion, aneurysm and pseudoaneurysm on Doppler ultrasound
- To differentiate the diagnostic features of vasculitis, atheroma, and thrombosis and aneurysmal dilatation of arteries and veins
- To detect and analyse acute and chronic diseases of the great vessels, including the aorta, pulmonary arteries, systemic and pulmonary veins
- To understand the radiological features of pericardial disease

SKILLS

- To perform ultrasound examinations of arteries and veins under supervision
- To apply techniques to reduce exposure doses for radiographic and CT examinations of the cardiac and vascular systems under supervision
- To plan and to protocol a n ECG-gated CT examination of the cardiac and vascular systems and to adapt it to the individual situation under supervision
- To plan and to protocol an MRI examination of the cardiac and vascular systems and to adapt it to the individual situation under supervision
- To report coronary CTA and basic cardiac MRI (myocarditis, myocardial viability) under supervision
- To perform proper common post-processing tasks for cardiovascular imaging studies, including multiplanar reformations (MPR), maximum intensity projections (MIP), minimum intensity projections (MinIP), volume rendering (VR), quantitative functional cardiac image analysis (segmentation for ventricular volumetry, flow measurement) and vessel analysis tools
- To provide clear and concise imaging reports
- To develop professional communication skills with referring clinicians (cardiologists, cardiovascular surgeons, pediatric cardiologists, etc.)

COMPETENCES AND ATTITUDES

- To justify diagnostic imaging examinations and/or interventional procedures of the cardiac and vascular systems under supervision
- To choose the best-suited method for evaluating disorders of the cardiac and vascular systems under supervision
- To obtain informed consent prior to diagnostic imaging and interventional procedures of the cardiac, vascular and lymphatic systems
- To choose optimal imaging parameters for radiographic, ultrasonographic, CT and MRI examinations of the cardiac and vascular systems under supervision

- To supervise and teach technical staff to ensure that appropriate images are obtained
- To report radiographic, ultrasonographic, CT and MRI examinations of the cardiac and vascular systems with respect to common diseases under supervision
- To appreciate own limitations and to identify when it is appropriate to obtain assistance in interpreting and reporting images of the cardiac and vascular systems
- To identify urgent and/or unexpected findings in imaging examinations of the cardiac and vascular systems and to communicate these timely and properly
- To communicate with patients and their relatives in order to explain their imaging findings of the cardiac and vascular systems
- To participate in and to perform under supervision at multidisciplinary meetings and/or (tumour) boards for diseases of the cardiac and vascular systems

B-I-3 CHEST RADIOLOGY

Content reviewed by ESTI (European Society of Thoracic Radiology)

INTRODUCTION

The aim of this curriculum in chest imaging is to ensure that the trainee develops core knowledge of the relative value of available imaging modalities with regard to normal chest and chest diseases. This knowledge will form the basis for further training (if desired) and also provide transferable skills that will equip the trainee to work as a specialist in any branch of radiology.

Physics, contrast media and radiation protection are covered in separate sections, and therefore are not included in detail in this section, unless of particular relevance to chest imaging.

KNOWLEDGE

- To describe the anatomy of the respiratory system, heart and vessels, the mediastinum and the chest wall on radiographs, CT and MRI
- To describe normal variants of the respiratory system, heart and vessels, mediastinum and the chest wall
- To understand the mean exposure doses of chest radiographs and chest CT examinations
- To understand techniques to reduce exposure doses of chest radiographs and chest CT examinations
- To describe the principles of digital imaging and image processing pertinent to chest radiology
- To understand the significance of generic signs on chest radiographs and CT
- To understand imaging referrals for tailored chest imaging
- To form a meaningful report with a conclusion and management plan

GENERIC SIGNS ON CHEST IMAGING

- To confidently identify the following structures on postero-anterior (PA) and lateral chest radiographs:
 - » Right upper, middle and lower lobes; left upper and lower lobes; and lingula
 - » Fissures – major, minor and azygos
 - » Airway – trachea, main bronchi, posterior wall of the intermediate bronchus and lobar bronchi
 - » Heart – position of the atria, ventricles, left atrial appendage and the location of the four cardiac valves
 - » Pulmonary arteries – main, right, left and interlobar
 - » Aorta – ascending, arch and descending aorta
 - » Arteries – brachiocephalic (innominate), carotid and subclavian arteries
 - » Veins – superior and inferior vena cava, azygos, left superior intercostal (“aortic nipple”) and left brachiocephalic (innominate) veins
 - » Components of the thoracic skeleton
 - » Mediastinal stripes and interfaces
 - » Aortopulmonary window
 - » Both hemidiaphragms
 - » Hilar structures
- To have an in-depth understanding of the significance of the following chest radiography signs:
 - » Silhouette sign – loss of the contour of the heart or diaphragm indicating an adjacent abnormality (e.g. atelectasis of the right middle lobe obscures the right-hand side of the heart’s border)

- » Air bronchogram – indicates airless alveoli and, therefore, a parenchymal process as distinguished from a pleural or mediastinal process
- » Air crescent sign – indicates solid material in a lung cavity, often due to a fungus ball, or crescentic cavitation in invasive fungal infection
- » Cervicothoracic sign – a mediastinal opacity that projects above the clavicles, situated posterior to the plane of the trachea, while an opacity projecting at or below the clavicles is situated anteriorly
- » Tapered margins – a lesion in the chest wall, mediastinum or pleura may have smooth tapered borders and obtuse angles with the chest wall or mediastinum, while parenchymal lesions usually form acute angles
- » Finger in glove sign – indicates bronchial impaction, e.g., in allergic bronchopulmonary aspergillosis, or other chronic obstructive process
- » Golden S-sign – indicates lobar collapse with a central mass, often due to an obstructing bronchogenic carcinoma in an adult
- » Deep sulcus sign on a supine radiograph – indicates pneumothorax
- To describe monitoring and support devices (“tubes and lines”) and to confidently identify them on imaging studies
- To describe the imaging features and the preferred placement of the following devices and lines and to list the complications associated with malpositioning:
 - » Endotracheal tube
 - » Central venous catheter
 - » Swan-Ganz catheter
 - » Nasogastric tube
 - » Chest tube/drain
 - » Intra-aortic balloon pump
 - » Pacemaker and pacemaker leads
 - » Implantable cardiac defibrillator and leads
 - » Left ventricular assistant device
 - » Atrial septal defect closure device
 - » Left atrial appendage occlusion devices
 - » Pericardial drain
 - » Extracorporeal life support cannulae
 - » Intra-oesophageal manometer, temperature probe or pH probe
 - » Tracheal or bronchial stent
- To describe the typical appearances of pleural effusion on erect, supine and lateral decubitus chest radiographs, and to list common causes of a large unilateral pleural effusion
- To describe the imaging features of pleural-based masses with bone destruction or infiltration of the chest wall on chest radiograph and CT and to list common causes
- To describe the imaging features of a unilateral elevation of one hemidiaphragm on chest radiographs and to list common causes (e.g. subdiaphragmatic abscess, diaphragm rupture, phrenic nerve involvement with lung cancer, post-cardiac surgery and eventration)
- To describe the clinical and imaging features of tension pneumothorax
- To describe the normal dimensions of the thoracic aorta
- To have an in-depth understanding of the Stanford A and B classification of aortic dissection and the implications of the classification for medical versus surgical management
- To know the features on radiographs and CT of diffuse interstitial and parenchymal lung disease, airways and obstructive lung disease
- To differentiate solitary and multiple pulmonary nodules, benign and malignant neoplasms, hyperlucencies and their potential aetiology and evaluation
- To differentiate thoracic diseases in immunocompromised patients and congenital lung disease
- To analyse and explain disorders of the pulmonary vascular system and great vessels

- To understand the diagnostic role of radiographs, scintigraphy, CT and MRI in the diagnostic evaluation of disorders of the pulmonary vascular system and great vessels
- To differentiate abnormalities of the chest wall, mediastinum and pleura

SKILLS

- To plan and to supervise the proper acquisition of chest radiographs, ventilation / perfusion imaging, chest CT, high-resolution chest CT and the CT pulmonary angiography (CTPA)
- To correctly position patients (newborns, infants, children and adults) for chest radiographs and chest CT examinations
- To plan and to report a CT examination of the chest and to adapt it to the individual situation
- To plan and to report an MRI examination of the chest and to adapt it to the individual situation
- To perform proper common post-processing tasks for thoracic imaging studies, including multiplanar reformations (MPR), maximum intensity projections (MIP), minimum intensity projections (MinIP) and vessel analysis tools
- To perform and interpret ultrasound examinations of the chest
- To perform aspirations of pleural fluid under image-guidance
- To form a meaningful report with a conclusion and management plan

COMPETENCES AND ATTITUDES

- To justify diagnostic imaging examinations and/or interventional procedures of the chest
- To choose the best-suited method for evaluating disorders of the chest
- To obtain informed consent from the patient prior to interventional procedures of the chest and/or diagnostic imaging
- To choose optimal imaging parameters for radiographic, ultrasonographic, CT and MRI examinations of the chest
- To design imaging protocols for CT examinations of the thorax, including the appropriate application of intravenous contrast, spatial and temporal resolution, inspiration/expiration and reconstruction/reformatting techniques
- To apply techniques to reduce exposure doses for radiographic and CT examinations of the chest
- To supervise and teach technical staff to ensure that appropriate images are obtained
- To interpret and report chest radiographs, ventilation/perfusion imaging, chest CT, high-resolution chest CT and CT pulmonary angiography (CTPA) with respect to common diseases
- To appreciate own limitations and to identify when it is appropriate to obtain assistance in interpreting and reporting images of the chest
- To identify urgent and/or unexpected findings in imaging examinations of the chest and to communicate these timely and properly
- To communicate with patients and their relatives in order to explain imaging findings on their chest imaging study

- To choose optimal biopsy routes and techniques
- To participate in and to perform under supervision at multi-disciplinary conferences and tumour boards for chest diseases

B-I-4

EMERGENCY RADIOLOGY

Content reviewed by ESER (European Society of Emergency Radiology)

INTRODUCTION

The aim of this curriculum in Emergency Radiology is to ensure that the trainee develops core knowledge of the relative value of available imaging modalities regarding traumatic and non-traumatic emergencies. Emergency Radiology is mainly embedded in a multidisciplinary context.

As a consequence, the curriculum will sometimes refer to transferable content from other subspecialty curricula. This knowledge will form the basis for further training and provide transferable skills that will equip the trainee to work as a specialist in any branch of radiology.

Physics, contrast media and radiation protection are covered in separate sections, and therefore are not included in detail in this section, unless of relevance to emergency imaging.

KNOWLEDGE

- To describe epidemiological data regarding emergencies
- To understand the common mechanisms of injury including acting forces and their distribution on human bodies
- To understand principles and basic application of estimating emergency severity such as the Injury Severity Score (ISS) for trauma cases and pain rating scales regarding the region of pain in non-traumatic cases
- To describe potentially critical legal aspects
- To describe hygiene regulations
- To describe guidelines and corresponding institutional Standard Operating Procedures/algorithms regarding emergency cases
- To describe relevant normal anatomy of the brain, spine, musculoskeletal system, lung, heart, mediastinum, diaphragm, abdominal organs and spaces, genito-urinary tract, venous and arterial system including topographic relationships and cross-sectional appearance
- To describe common normal variants and distinction from acute pathology
- To describe the various radiological modalities and techniques employed in ER including their respective strengths, weaknesses, opportunities and threats regarding ER
- To describe factors and effects of radiation dose as well as techniques for dose reduction
- To describe criteria for good, reasonable/acceptable, poor and insufficient image quality
- To understand the potential risks and benefits of modality-dependent contrast media including effects of oral, rectal or bladder filling
- To describe the various phases of intravenous contrast media application (plain, arterial, portal, delayed, hepatobiliary, urographic) and their respective uses according to the clinical problem
- To identify the typical appearance of pericardial effusion, pleural effusion, pneumothorax and free abdominal fluids in extended Focused Assessment with Sonography for Trauma (eFAST) or emergency thoracoabdominal US if working in an institution where eFAST is not performed.

- To describe respective imaging algorithms for various non-traumatic emergency cases
- To describe respective imaging algorithms for low-energy and high-energy traumatic emergencies
- To describe the relevant pathophysiology, clinical presentation and modality dependent imaging findings of fractures, hypovolemic shock, pneumothorax, pulmonary oedema, pericardial tamponade, obstructive and paralytic ileus, hollow organ perforation or anastomotic insufficiency, organ laceration or rupture (heart, liver, spleen, kidney, pancreas), ischemia, embolism, thrombosis, arterial dissection or rupture, urinary calculi, acute cholestasis, acute neurological deficits, severe inflammatory conditions (such as meningitis, acute osteomyelitis, abscesses, severe pneumonia, cholecystitis, appendicitis, ...), ovarian and testicular torsion
- As not covered by content above:
 - » To describe additional knowledge content of other subspecialty curricula in cases where patients may often present initially to those experts such as musculoskeletal, paediatric, neurological, gynecological / obstetrical and male genitourinary emergencies
 - » To describe the relevant modality-dependent imaging findings of tubes, drains and catheters, especially with regards to positions
 - » To describe radiological standard procedures in polytrauma cases, CT under resuscitation and mass casualty incidents
 - » To describe theory, indications and contraindications for image-guided interventional procedures in emergency settings

SKILLS

- To assess current guidelines provided by national and international ER and other relevant subspecialty bodies
- To properly perform or supervise patient positioning and protocol choice including the application of techniques to reduce dose exposure
- To perform under supervision or assist in:
 - » e-FAST or emergency thoracoabdominal US
 - » sonography and contrast-enhanced ultrasonography of emergency cases
 - » femoral artery and venous puncture techniques
 - » image-guided drainage of fluid collections
 - » percutaneous cholecystectomy and nephrostomy
 - » percutaneous transhepatic drainage of the biliary tract
 - » other interventional emergency procedures under imaging guidance, particularly in bleeding control
- To identify modality and body region dependent common imaging findings in emergency cases such as fracture patterns, dislocations, cartilage injury, ileus signs, free air and fluids, acute bleeding, infarctions, embolism
- To classify and triage imaging findings from each modality from immediate/life-threatening to non-life threatening
- To interpret the relevant modality-dependent imaging findings of iatrogenic placement regarding tube, drainage or catheter location
- To assist in image interpretation or therapy of >1500 emergency cases (>500 CR, >200 eFAST or emergency abdominal US, >500 CT including >100 polytrauma cases and cardiovascular emergency cases, >50 MRI as well as embolisations and drainage of fluid collections). These cases have to be distributed proportionally over the body regions and the more common pathologies

COMPETENCES AND ATTITUDES

- To obtain and interpret relevant clinical information
- To differentiate high-risk from low-risk patients before imaging
- To differentiate and prioritise findings with respect to their urgency after imaging
- To be able to 'screen' as fast as possible for life-threatening findings (e.g. for CT: <10 min after scan start) using an optimised infrastructure and selective image reading in case of high-risk patients
- To understand the respective advantages and disadvantages of different imaging options in emergency cases
- To choose the best-suited imaging modality and protocol parameters and, if necessary, to put imaging techniques into the most appropriate diagnostic pathway considering advantages and limitations of the different modalities, diagnostic accuracy and speed, amount of radiation exposure and ethically motivated individual risk/benefit-analysis with respect to case severity, time-to-diagnose/therapy, patient age and sex
- To communicate as quickly and effectively as possible with referring physicians and supervisory staff
- To participate at multidisciplinary treatment, morbidity and mortality conferences
- To participate in Quality Assessment and Quality Monitoring for emergency care
- To participate at multidisciplinary meetings to discuss challenging emergency cases
- To communicate with patients and their relatives with respect to consent as well as bringing bad news in a multidisciplinary context
- To demonstrate a responsible work ethic
- To appreciate own limitations and to identify when it is appropriate to add further imaging and/or obtain assistance in image interpretation
- To understand principles, physical properties, toxic effects, anaphylactoid reactions and biological effects of imaging contrast media
- To outline the best contrast material and its optimal use according to the imaging technique and the clinical problem
- To describe the various timing phases of contrast media application and their respective values according to the clinical problem
- To describe the fundamentals of intravascular bolus kinetics and constant rate input
- To describe the physiology of renal excretion of contrast medium
- To describe enhancement curves within renal compartments after injection of contrast agents
- To list concentrations and doses of contrast agents used intravenously
- To define the nephrotoxicity of contrast media
- To list risk factors of contrast media nephrotoxicity

B-I-5 GASTROINTESTINAL AND ABDOMINAL RADIOLOGY

Content reviewed by ESGAR (European Society of Gastrointestinal and Abdominal Radiology)

INTRODUCTION

The aim of this curriculum in gastrointestinal and abdominal imaging is to ensure that the trainee develops core knowledge of the relative value of available imaging modalities with regard to normal abdomen, benign, acute and oncological conditions in abdomen. This knowledge will form the basis for further training (if desired) and also provide transferable skills that will equip the trainee to work as a specialist in any branch of radiology.

Physics, contrast media and radiation protection are covered in separate sections, and therefore are not included in detail in this section, unless of particular relevance to gastrointestinal and abdominal imaging.

KNOWLEDGE

- To describe the normal anatomy of the abdomen and the main variants of the internal viscera, abdominal organs, omentum, mesentery and peritoneum, abdominal wall and pelvic floor on abdominal radiographs, contrast studies, CT, ultrasound and MRI
- To describe the arterial, venous and lymphatic drainage of the relevant organs in the abdomen
- To understand the principal aspects of embryology of the oesophagus, stomach, duodenum, small bowel, appendix, colon, rectum, anus, pancreas, liver, biliary tract and spleen
- To describe the main anatomical variants that may mimic disease in abdominal imaging
- To describe the clinical presentation and natural history of the most common and/or severe diseases of the abdomen and pelvis and the principles of their treatment
- To know the diagnostic features of common benign abnormalities related to the abdominal solid organs and bowel
- To understand normal post-procedure imaging related to the most common surgical and interventional radiology procedures
- To describe the imaging features of abdominal trauma and acute conditions, including perforation, haemorrhage, inflammation, infection, obstruction, ischaemia and infarction affecting the abdominal solid organs and gastrointestinal tract on radiographs, ultrasound and CT
- To describe the imaging features of the most common and/or severe chronic diseases of the abdomen
- To describe the patterns of growth and spread of the most common tumours of the solid abdominal organs and gastrointestinal tract and how to apply the principles of oncologic staging to guide management
- To identify imaging features in regard to the stage and extent of tumours, including features that indicate non-resectability
- To describe the basic principles and standards of post-therapy imaging evaluation (tumour, inflammation)
- To understand the main indications and techniques of interventional radiology as applied to abdominal diseases
- To understand the mean exposure doses of abdominal radiographs and of abdominal CT examinations
- To understand techniques to reduce exposure doses of abdominal radiographs and of abdominal CT examinations

- To understand both the technique and the role of associated examinations like endoscopy, endoscopic ultrasound and nuclear medicine (including SPECT and hybrid imaging SPECT/CT, PET/CT, PET/MRI)
- To understand the role of imaging techniques in the evaluation of acute abdomen in pregnancy
- To have a basic understanding of radiotracers used in hybrid imaging in gastrointestinal and abdominal diseases
- To understand the basic principles and the main applications of quantification and functional imaging in abdominal diseases, such as quantification of liver fat, iron or fibrosis, tumour perfusion and bowel inflammation
- To understand the rationale and basic principles of sequences for MRI in abdominal diseases including diffusion-weighted imaging

SKILLS

- To recognise proper positioning of abdominal radiographs for adults, newborns, infants and children
- To plan a CT examination of the abdomen and to adapt it to the individual clinical condition in regard to intravenous contrast medium, contrast phase and intraluminal contrast medium application, with a dose as low as reasonably achievable
- To perform trans-abdominal ultrasound examinations of the gastrointestinal system, abdominal viscera and their vessels, including Doppler sonography
- To observe contrast-enhanced ultrasound studies of the abdominal viscera
- To observe angiography and vascular and non-vascular-interventional techniques in gastrointestinal disease
- To observe CT colonography examinations
- To perform common post-processing tasks for abdominal imaging studies, including multiplanar reformations (MPR), maximum intensity projections (MIP), minimum intensity projections (MinIP) and vessel analysis tools

COMPETENCES AND ATTITUDES

- To justify diagnostic imaging examinations and/or basic interventional procedures of the abdomen and/or gastrointestinal system
- To choose the most appropriate modality for evaluating disorders of the abdomen and/or gastrointestinal system
- To advise on required patient preparation (e.g. fasting, bladder voiding, oral contrast administration,...)
- To communicate with the patient in order to obtain informed consent prior to diagnostic imaging and interventional procedures of the abdomen and/or gastrointestinal system
- To choose optimal imaging parameters for radiographic, ultrasonographic CT and MRI of the abdomen and/or gastrointestinal system
- To interpret and report abdominal radiographs, ultrasonographic examinations, abdominal CT studies and MRI examinations of the upper abdomen, small bowel, rectum and anal canal
- To report oncological studies according to international standards (TNM, RECIST, WHO) applicable to the specific situation
- To appreciate own limitations and to identify when it is appropriate to obtain assistance in interpreting and reporting images of the abdomen and gastrointestinal system

- To identify urgent and/or unexpected findings in imaging examinations of the abdomen and gastrointestinal system and to communicate these in a timely fashion and properly
- To communicate with patients and their relatives in order to explain their imaging findings in the abdomen and gastrointestinal system
- To participate in and to perform under supervision at multidisciplinary conferences and tumour boards for diseases of the abdomen and gastrointestinal system

B-I-6

GYNAECOLOGICAL AND OBSTETRIC RADIOLOGY

Content reviewed by ESUR (European Society of Urogenital Radiology)

INTRODUCTION

The aim of this curriculum in gynaecological and obstetric imaging is to ensure that the trainee develops core knowledge of the relative value of available imaging modalities with regard to normal female reproductive organs and female reproductive organs disease. This knowledge will form the basis for further training (if desired) and also provide transferable skills that will equip the trainee to work as a specialist in any branch of radiology.

Physics, contrast media and radiation protection are covered in separate sections, and therefore are not included in detail in this section, unless of particular relevance to gynaecological and obstetric imaging.

KNOWLEDGE

- To describe the normal anatomy of the female reproductive organs
- To understand the physiological changes affecting normal imaging anatomy of the female reproductive organs throughout the lifespan
- To understand the physiological changes of the female reproductive organs during pregnancy
- To understand the mean exposure doses of radiographs, hysterosalpingography and CT examinations of the female reproductive organs
- To understand techniques to reduce exposure doses of radiographs and CT examinations of the female reproductive organs
- To describe the clinical presentation and natural history of the most common and/or severe diseases of the female reproductive organs
- To understand normal post-procedure imaging of the female reproductive organs related to previous treatment such as surgery or interventional radiology
- To differentiate imaging features of tumours of the female reproductive organs
- To identify imaging features in regard to the stage and extent of tumours of the female reproductive organs, including features that indicate non-resectability
- To understand the imaging features of common disorders associated with pregnancy and delivery
- To understand the main indications and techniques of interventional radiology as applied to the female reproductive organs

SKILLS

- To perform a transabdominal and, where possible, transvaginal ultrasound in common gynaecological disorders
- To plan a CT examination in patients with common gynaecological disorders and to adapt it to the individual situation with a dose as low as reasonably achievable
- To plan an MRI examination of the female reproductive organs and to adapt it to the individual situation, also in regard to the potential use of intravenous contrast
- To perform imaging examinations for infertility work-up
- To perform proper common post-processing tasks for imaging studies of the female reproductive organs

COMPETENCES AND ATTITUDES

- To justify diagnostic imaging examinations and/or interventional procedures of the female reproductive organs
- To choose the best-suited method for evaluating disorders of the female reproductive organs
- To communicate with the patient in order to obtain informed consent prior to diagnostic imaging and interventional procedures female reproductive system
- To choose optimal imaging parameters for radiographic, ultrasonographic, CT and MRI examinations of the female reproductive organs
- To apply techniques to reduce exposure doses for radiographic and CT examinations of the female reproductive organs
- To choose the optimally suited imaging modality for pregnant patients
- To design imaging protocols for CT examinations of the female reproductive organs and for staging in patients with tumours of the female reproductive organs
- To design imaging protocols for MRI examinations of the female reproductive organs including the appropriate application of intravenous contrast and spatial and temporal resolution
- To supervise and teach technical staff to ensure that appropriate images of the female reproductive organs are obtained
- To interpret and report radiographs, CT and MRI examinations of patients with disorders of the female reproductive system
- To report oncological studies in patients with tumours of the female reproductive system according to FIGO stage
- To appreciate own limitations and to identify when it is appropriate to obtain assistance in interpreting and reporting images of the female reproductive system
- To identify urgent and/or unexpected findings in imaging examinations of the female reproductive system and to communicate these timely and properly
- To communicate with patients and their relatives in order to explain their imaging findings in disorders of the female reproductive system
- To participate in and to perform under supervision at multidisciplinary conferences and tumour boards for diseases of the female reproductive system

B-I-7

HEAD AND NECK RADIOLOGY

Content reviewed by ESHNR (European Society of Head and Neck Radiology)

INTRODUCTION

The aim of this curriculum in head and neck imaging is to ensure that the trainee develops core knowledge of the relative value of available imaging modalities with regard to the head and neck including maxillofacial and dental region. The core knowledge will include normal anatomy, important anatomical variants, including pseudolesions and head and neck pathology. This knowledge will form the basis for further training (if desired) and also provide transferable skills that will equip the trainee to work as a specialist in any branch of radiology.

Physics, contrast media and radiation protection are covered in separate sections, and therefore are not included in detail in this section, unless of particular relevance to head and neck imaging.

KNOWLEDGE

- To describe the normal anatomy and common anatomical variants of the head and neck, including skull base, temporal bone (including the inner ear), paranasal sinuses, the oral cavity, pharynx and larynx, salivary glands, thyroid and parathyroid glands, thoracic inlet, orbit, teeth and the temporomandibular joint
- To recall common congenital lesions of the head and neck, including the skull base, temporal bone, paranasal sinuses, the oral cavity, pharynx and larynx, the inner ear, orbit, teeth and the temporomandibular joint
- To understand common manifestations of diseases of the eye and orbit including trauma, foreign bodies, inflammation and tumours
- To understand common imaging manifestations of maxillo-facial trauma and tumours and disorders of the teeth
- To understand common imaging manifestations of lesions and abnormal function of the temporomandibular joint
- To be aware of the role of radionuclide imaging in disorders of the thyroid and parathyroid glands
- To understand common imaging manifestations of trauma, inflammation, infection and tumours of the skull base, temporal bone, paranasal sinuses, oral cavity, larynx and pharynx, thyroid and parathyroid, and salivary glands
- To understand the role of ultrasound- guided fine needle aspiration cytology (FNAC) and tru-cut biopsies in particular of the salivary glands, lymph nodes and the thyroid, but also other, mainly superficial, areas of the head and neck

SKILLS

- To observe perform fluoroscopic examinations of the head and neck region, including barium swallows and sialography
- To observe and perform under supervision ultrasound examinations of the neck, including thyroid, parathyroid, lymph nodes and salivary glands
- To plan a CT in patients with common disorders of the head and neck region and to adapt it to the individual situation with a dose as low as reasonably achievable
- To plan an MRI examination of the head and neck region for the most common indications and to adapt it to the individual situation
- To perform proper common post-processing tasks for imaging studies of the head and neck region including multiplanar reformations (MPR) and maximum intensity projections (MIP)
- To observe image-guided interventional techniques of the head and neck region, e.g. FNAC biopsy of the thyroid gland and tru-cut biopsy of cervical lymph nodes

COMPETENCES AND ATTITUDES

- To justify diagnostic imaging examinations and/or interventional procedures of the head and neck
- To choose the best-suited method for evaluating disorders of the head and neck
- To communicate with the patient in order to obtain informed consent prior to diagnostic imaging and/or interventional procedures of the head and neck
- To understand optimal imaging parameters for radiographic, ultrasonographic, CT, cone beam CT and MRI examinations of the head and neck
- To apply techniques to reduce exposure doses for radiographic and CT examinations of the head and neck
- To supervise and design imaging protocols for CT and cone beam CT examinations of the head and neck, including staging examinations in tumours of the head and neck region and to adapt the examination depending on the imaging findings
- To supervise pre-defined imaging protocols for MRI examinations of the head and neck and to design MRI protocols for common indications
- To supervise and teach technical staff to ensure that appropriate images of the head and neck region are obtained
- To recognise suboptimal image quality and its causes
- To interpret and report radiographs, ultrasonographic examinations, CT studies, cone beam CT studies and MRI examinations for common diseases of the head and neck region
- To report oncological studies of the head and neck region according to international standards (TNM) applicable to the specific situation
- To appreciate own limitations and to identify when it is appropriate to obtain assistance in interpreting and reporting images of the head and neck region
- To identify urgent and/or unexpected findings in imaging examinations of the head and neck region and to communicate these timely and properly
- To communicate with patients in order to explain common imaging findings in the head and neck and to observe how to communicate bad news
- To attend as an observer multidisciplinary conferences and tumour boards for diseases of the head and neck region

B-I-8

INTERVENTIONAL RADIOLOGY

Content reviewed by CIRSE (Cardiovascular and Interventional Radiological Society of Europe)

INTRODUCTION

The aim of this curriculum in interventional radiology is to ensure that the trainee develops core knowledge of the relative value of available imaging modalities with regard to common interventional procedures. This knowledge will form the basis for further training (if desired) and also provide transferable skills that will equip the trainee for the performance and interpretation of diagnostic vascular and non-vascular techniques and an understanding in any branch of radiology.

Physics, contrast media and radiation protection are covered in separate sections, and therefore are not included in detail in this section, unless of particular relevance to interventional radiology.

KNOWLEDGE

- To describe the normal anatomy, including common normal variants of the relevant organ, lymphatic, arterial and venous systems and its relevance to interventional radiology
- To describe typical access approaches to common disorders in vascular and non-vascular interventional radiology including biopsy and drainage
- To know the role of different imaging modalities in planning and guiding interventional procedures
- To know how to optimise patient and staff safety during interventional procedures, including understanding of the CIRSE checklist and radiation protection
- To know the different types of guidewires and catheters and understand their use
- To know about the different types of needles used for arterial access, including micro-access systems
- To understand the range of treatment strategies for common interventional radiological procedures
- To describe typical approaches for image-guided ablative techniques
- To understand the risk involved in common interventional techniques and their basic management
- To understand the use, dosage and administration of local anaesthetics
- To understand the pharmacology, administration and patient supervision required for the safe administration of intravenous sedation
- To know about safe monitoring of patients during and post procedure
- To describe the standard management emergencies, including resuscitation techniques
- To describe typical catheterisation techniques and the principles of selective catheterisation and embolisation
- To understand the indications for nephrostomy drainage, abscess drainage and pleural drainage

SKILLS

- To perform basic arterial and venous catheterisation techniques under supervision
- To perform peripheral arteriography and angioplasty under supervision
- To perform image-guided abscess drainages
- To perform image-guided nephrostomy of dilated renal collecting systems under supervision
- To perform image-guided biopsies (at least of superficial structures)
- To perform emergency procedures in life-threatening disorders, including cardio-pulmonary resuscitation

COMPETENCES AND ATTITUDES

- To justify indications for interventional radiological procedures
- To choose the best access routes for an interventional procedure
- To be able to carry out informed consent prior to an interventional procedure
- To use imaging appropriately for interventional procedures
- To optimise techniques to minimise radiation doses for interventional procedures, both for the patient and for the radiologist and staff
- To supervise and teach technical staff to ensure that appropriate support is provided for interventional procedures
- To safely use sedo-analgesia for pain management in patients undergoing interventional radiological procedures
- To ensure adequate monitoring of patients during procedures
- To appreciate own limitations and to identify when it is appropriate to obtain assistance in interventional procedures
- To manage and coordinate emergency situations arising from and/or during interventional procedures
- To communicate with patients and their relatives in order to explain the outcome of the interventional procedure
- To be involved in multidisciplinary team meetings for patients with potential indications for interventional procedures
- To be able to review and manage patients following interventional radiological procedures
- To be involved with and carry out clinical consultations of patients pre- and postprocedures and attend multidisciplinary meetings (MDM)

B-I-9

MUSCULOSKELETAL RADIOLOGY

Content reviewed by ESSR (European Society of Musculoskeletal Radiology)

INTRODUCTION

The aim of this curriculum in musculoskeletal imaging is to ensure that the trainee develops core knowledge of the relative value of available imaging modalities with regard to normal, variants and pathology of musculoskeletal system. This knowledge will form the basis for further training (if desired) and also provide transferable skills that will equip the trainee to work as a specialist in any branch of radiology.

Physics, contrast media and radiation protection are covered in separate sections, and therefore are not included in detail in this section, unless of particular relevance to musculoskeletal imaging.

KNOWLEDGE

- To describe the normal anatomy of the musculoskeletal system
- To be familiar with normal skeletal variants that mimic disease
- To describe common congenital dysplasias of the musculoskeletal system
- To appreciate the value of different imaging techniques in musculoskeletal disorders
- To understand common imaging presentations of trauma involving the skeleton and soft tissue
- To understand the imaging presentation of degenerative disorders of the musculoskeletal system and to appreciate their clinical relevance
- To understand the imaging manifestations of musculoskeletal infection
- To understand the imaging manifestations of inflammatory musculoskeletal diseases, metabolic diseases, including osteoporosis
- To describe the typical radiographic features of common bone tumours

SKILLS

- To perform basic ultrasound examinations of the musculoskeletal system (major joints and tendons) for common musculoskeletal disorders as described in the ESSR guidelines
- To know the proper X-ray views to investigate the musculoskeletal system especially after trauma
- To plan a CT examination in patients with common disorders of the musculoskeletal system and to adapt it to the individual situation with a dose as low as reasonably achievable
- To plan an MRI examination of the musculoskeletal system and to adapt it to the individual situation
- To perform proper common post-processing tasks for imaging studies of the musculoskeletal system including multiplanar reformations (MPR) and maximum intensity projections (MIP)
- To perform image-guided application of intraarticular contrast media for MR arthrography or CT arthrography under supervision

COMPETENCES AND ATTITUDES

- To justify diagnostic imaging examinations of the musculoskeletal system
- To choose the best-suited method for evaluating disorders of the musculoskeletal system
- To communicate with the patient in order to obtain informed consent prior to diagnostic imaging of the musculoskeletal system
- To choose optimal imaging parameters for radiographic, ultrasonographic, CT and MRI examinations of the musculoskeletal system
- To apply techniques to reduce exposure doses for radiographic and CT examinations of the musculoskeletal system
- To design imaging protocols for CT examinations of the musculoskeletal system
- To design imaging protocols for MRI examinations of the musculoskeletal system
- To supervise and teach technical staff to ensure that appropriate images of the musculoskeletal system are obtained
- To interpret and report radiographs, ultrasonographic examinations, CT studies and MRI examinations of the musculoskeletal system
- To appreciate own limitations and to identify when it is appropriate to obtain assistance in interpreting and reporting images of the musculoskeletal system
- To identify urgent and/or unexpected findings in imaging examinations of the musculoskeletal system and to communicate these timely and properly
- To communicate with patients and their relatives in order to explain the musculoskeletal procedures and imaging findings
- To participate in and to perform under supervision at musculoskeletal multidisciplinary conferences

B-I-10 NEURORADIOLOGY

Content reviewed by ESNR (European Society of Neuroradiology)

INTRODUCTION

The aim of this curriculum in neuroradiology is to ensure that the trainee develops core knowledge of the relative value of available imaging modalities with regard to normal, functional and pathological changes of the brain, skull, skull base, extracranial head, spine, spinal cord, peripheral nervous system and interventional procedures. This knowledge will form the basis for further training (if desired) and also provide transferable skills that will equip the trainee to work as a specialist in any branch of radiology.

Physics, contrast media and radiation protection are covered in separate sections, and therefore are not included in detail in this section, unless of particular relevance to neuroradiology.

KNOWLEDGE

- To describe normal anatomy and normal variants of the brain, skull, skull base, extracranial head, spine and spinal cord, and peripheral nervous system
- To describe the normal anatomy of the cranio-cervical and spinal arterial and venous system, and its relevance to diagnostic and interventional neuroradiology
- To describe characteristic endovascular and percutaneous approaches to common disorders in interventional neuroradiology (brain, skull, skull base, extracranial head, and spine/spinal cord)
- To recall common congenital lesions of the brain, skull, skull base, extracranial head, spine and spinal cord
- To understand the rationale for selecting certain imaging techniques and the use of contrast administration in diagnosing and monitoring diseases of the brain, skull, skull base, extracranial head, spine and spinal cord, and peripheral nervous system
- To describe the potential risks and benefits of modality-dependent contrast media
- To understand the role of advanced CT and MR techniques, including perfusion CT and MR, diffusion tensor imaging, functional MRI and proton MR spectroscopy in diagnosing and monitoring diseases of the central and peripheral nervous system, skull, skull base, extracranial head and spine
- To understand imaging features of ischaemic and haemorrhagic stroke and other common vascular lesions of the brain and spinal cord and to differentiate these from other disorders
- To understand imaging features of traumatic brain injury and spinal trauma and to comprehend their neurological sequelae
- To understand imaging features and differential diagnoses of metabolic, infectious, inflammatory, toxic, and degenerative diseases involving the nervous system
- To understand imaging features of degenerative disease of the spine
- To understand imaging features of benign and malignant tumours of the brain, skull, skull base, extracranial head, spine and spinal cord, and peripheral nervous system

- To appreciate the role of nuclear medicine, including SPECT and hybrid imaging techniques (PET/CT, PET/MR) in the diagnostic evaluation of disorders involving the brain, skull, skull base, extracranial head and spine
- To have a basic understanding of radiotracers used in neuroimaging

SKILLS

- To perform ultrasonographic examinations of the carotid arteries, including Doppler-sonographic studies
- To observe ultrasonographic and Doppler-sonographic studies of intracranial vessels
- To perform basic vascular catheterisation and percutaneous techniques under supervision
- To observe diagnostic and interventional supra-aortic, intracranial, and spinal digital subtraction angiographies
- To observe image-guided puncture of the spine with and without contrast media application (myelography, diagnostic lumbar puncture)
- To plan CT examinations in patients with common disorders of the brain, skull, skull base, extracranial head and spine and to adapt them to the individual situation with a dose as low as reasonably achievable, including the decision for or against contrast administration
- To plan MRI examinations in patients with common disorders of the brain, skull, skull base, extracranial head and spine and to adapt them to the individual situation, including the decision for or against contrast administration
- To perform proper common post-processing tasks for imaging studies of the brain spine / spinal cord, skull base, extracranial head and peripheral nervous system, including multiplanar reformations (MPR), maximum intensity projections (MIP) and vessel analysis tools

COMPETENCES AND ATTITUDES

- To justify diagnostic imaging examinations and/or interventional procedures of the brain, skull, skull base, extracranial head, spine and spinal cord, and peripheral nervous system
- To choose the best-suited method for evaluating disorders of the brain, skull, skull base, extracranial head, spine and spinal cord, and peripheral nervous system
- To communicate with the patient in order to obtain informed consent prior to diagnostic imaging and/or interventional procedures of the brain, skull, skull base, extracranial head, spine and spinal cord, and peripheral nervous system
- To choose optimal imaging parameters for X-ray, ultrasound / Doppler-ultrasound, CT and MRI examinations of the brain, skull, skull base, extracranial head, spine and spinal cord, and peripheral nervous system.
- To apply techniques to reduce radiation dose for X-ray and CT examinations of the brain, skull, skull base, extracranial head, spine and spinal cord, and peripheral nervous system
- To design imaging protocols for CT examinations of the brain, skull, skull base, extracranial head, spine and spinal cord, and peripheral nervous system
- To design imaging protocols for MRI examinations of the brain, skull, skull base, extracranial head, spine and spinal cord, and peripheral nervous system
- To supervise and teach technical staff to ensure that appropriate images of the brain, skull, skull base, extracranial head, spine and spinal cord, and peripheral nervous system are obtained
- To interpret and report X-ray, ultrasound / Doppler-ultrasound, CT and MRI examinations of the brain, skull, skull base, extracranial head, spine and spinal cord, and peripheral nervous system

- To report oncological studies of the brain, skull, skull base, extracranial head, spine and spinal cord, and peripheral nervous system according to international standards (TNM) applicable to the specific situation
- To appreciate own limitations and to identify when it is appropriate to obtain assistance in interpreting and reporting images of the brain, skull, skull base, extracranial head, spine and spinal cord, and peripheral nervous system
- To identify urgent and/or unexpected findings in imaging examinations of the brain, skull, skull base, extracranial head, spine and spinal cord, and peripheral nervous system and to communicate these timely and properly
- To communicate with patients and their relatives in order to explain their imaging findings of the brain, skull, skull base, extracranial head, spine and spinal cord, and peripheral nervous system
- To participate in and to perform under supervision at multidisciplinary conferences, for diseases of the brain, skull, skull base, extracranial head, spine and spinal cord, and peripheral nervous system

B-I-11 PAEDIATRIC RADIOLOGY

Content reviewed by ESPR (European Society of Paediatric Radiology)

INTRODUCTION

The aim of this curriculum in paediatric radiology is to ensure that the trainee develops core knowledge of the relative value of available imaging modalities with regard to normal development, congenital anomalies and acquired diseases that may affect the neonate, infant and child. This knowledge will form the basis for further training (if desired) and also provide transferable skills that will equip the trainee to work with children in any branch.

Physics, contrast media and radiation protection are covered in separate sections, and therefore are not included in detail in this section, unless of particular relevance to paediatric imaging.

KNOWLEDGE

- To describe normal paediatric anatomy and normal variants, with particular relevance to normal maturation and growth
- To understand imaging features of common disease entities specific to the paediatric age group
- To be familiar with principles of establishing a child-friendly environment and conduct
- To have an in-depth understanding of the relative values, strengths and weakness of as well as indications for radiography, fluoroscopy, ultrasound, CT and MRI in children
- To understand both the technique and the role of nuclear medicine (including SPECT, and hybrid imaging SPECT/CT, PET/CT, PET/MRI) in paediatric imaging
- To understand the increased vulnerability of children to ionising radiation
- To have an in-depth understanding of the ALARA principle and the special requirements for radiation safety and contrast material dosage in relation to body mass for the paediatric population
- To understand basic embryology that will enable appreciation of the location and characteristics of common brain, spine, head and neck, lung, abdominal, gastrointestinal and urogenital congenital disorders
- To recall common congenital disorders of the different body regions and their respective relevance for the child's further development
- To be familiar with the differences in mechanism of injury, indication for imaging and of imaging protocols between adult and childhood trauma (including non-accidental trauma)
- To be familiar with the imaging features of common disorders of the brain and spine in neonates, infants and children, including traumatic brain injury (accidental and non-accidental), congenital disorders of the brain and spine, infection and inflammation, hypoxic injury to the brain, brain haemorrhage and brain tumours
- To be familiar with the imaging features of common disorders of the chest in the paediatric population including bronchiolitis, pneumonia, pleural effusion, air-leaks, foreign body aspiration, mediastinal masses, thymus and variants, malformations of the airways and great vessels and oesophageal atresia
- To be familiar with the imaging features of neonatal intestinal obstruction, gut malrotation, necrotising enterocolitis, Hirschsprung's disease and imperforate anus

- To be familiar with the imaging strategies (including when and when not to image) and be aware of the most common underlying diseases in acute and chronic abdominal pain, in children with vomiting and in abdominal distension in children
- To be familiar with the imaging strategies in dilatation of the urinary tract and urinary tract infection and be familiar with predisposing congenital anomalies of the urinary tract (CAKUT), including vesicouretral reflux
- To be familiar with imaging of renal cystic disease in children
- To be familiar with the clinical and imaging presentation of acute ovarian torsion and acute scrotum in children
- To be familiar with the imaging features of abdominal masses in children
- To be familiar with the most common causes of bone pain in children specific to the different paediatric age groups
- To keep in mind the normal features of the musculoskeletal system typical of each age group
- To be aware of the imaging features of the most frequent disorders of the skeletal system in the paediatric population, in particular traumatic (accidental and non-accidental), oncological, infectious, rheumatological, growth-related and bone-dysplasias
- To understand indications and the range of treatment strategies for common interventional radiological procedures in neonates, infants and children

SKILLS

- To perform ultrasound examinations of the head in hydrocephalus, benign enlargement of sub-arachnoid spaces, subependymal and intraventricular haemorrhage, periventricular white matter injury and tumours in newborns and infants under supervision
- To observe and perform ultrasound examinations of the neck and soft tissues, including palpable lumps, thyroid, parathyroid, lymph nodes, salivary glands under supervision
- To perform ultrasound examinations of the chest for evaluating pleural effusion, chest consolidation and normal thymus in newborns, infants and children under supervision
- To perform ultrasound examinations of the abdomen for acute intestinal intussusception, acute appendicitis
- To perform ultrasound examinations of the abdomen intestinal obstruction and volvulus, hypertrophic pyloric stenosis, inguinal hernia, in newborns, infants and children under supervision
- To perform ultrasound examinations of the abdomen for masses, uretero-hydronephrosis, urolithiasis and nephrocalcinosis as well as cystic disease of the kidney in newborns, infants and children under supervision
- To perform ultrasound examinations of the abdomen for, uretero-hydronephrosis, urolithiasis and nephrocalcinosis
- To perform ultrasound examinations of the pelvis for acute pelvic pain in female infants, children and adolescents under supervision
- To perform ultrasound examinations of the scrotum for acute scrotal pain, scrotal masses in male infants, children and adolescents under supervision
- To perform ultrasound examinations of the hip in congenital hip dysplasia and transient synovitis in newborns, infants and children under supervision
- To perform routine fluoroscopic contrast medium studies of the gastrointestinal system and urinary tract including upper GI, lower GI, contrast studies, voiding cystourethrography in newborns, infants and children under supervision

- To supervise radiographs in newborns, infants and children and to recognise proper position and suboptimal image quality
- To plan, decide on protocol and to supervise the conduct of CT examinations in newborns, infants and children and to adapt it to the individual situation with special consideration of radiation protection in the paediatric population
- To plan, decide on protocol and to supervise the conduct of MRI examinations in newborns, infants and children and to adapt it to the individual situation
- To perform proper common post-processing tasks for paediatric imaging studies, including multiplanar reformations (MPR)
- To observe interventional techniques in paediatric radiology, e.g., management of intussusception, biopsies and drainages
- To observe nuclear imaging studies with gamma cameras, SPECT and PET/CT in children
- To describe the standard procedure in emergency situations, including resuscitation techniques in children
- To ensure adequate monitoring of patients during sedation or interventional procedures

COMPETENCES AND ATTITUDES

- To justify diagnostic imaging examinations in neonates, infants and children
- To choose the best-suited method for evaluating common disorders in the paediatric population
- To communicate with the parents / caretakers in order to explain the procedures and obtain informed consent prior to diagnostic imaging in neonates, infants and children
- To choose optimal imaging parameters for radiographic, ultrasonographic / Doppler-sonographic, CT and MRI examinations of neonates, infants and children
- To apply techniques to reduce exposure doses for radiographic, fluoroscopic and CT examinations of neonates, infants and children
- To design optimised imaging protocols for CT examinations of neonates, infants and children
- To design optimised imaging protocols for MRI examinations of neonates, infants and children
- To supervise and teach technical staff to ensure that appropriate images of neonates, infants and children are obtained
- To recognise suboptimal image quality and its causes in paediatric imaging
- To interpret and report radiographs, fluoroscopy studies, ultrasound examinations, CT studies and MRI examinations of neonates, infants and children in regard to common disorders in this age group
- To appreciate own limitations and to identify when it is appropriate to obtain assistance in interpreting and reporting images of neonates, infants and children
- To identify urgent and/or unexpected findings in imaging examinations of the neonates, infants and children and to explicitly communicate these a timely fashion
- To communicate with children, parents / caregivers in order to explain the imaging findings of their children
- To communicate with children and adolescents in an age-appropriate matter in order to explain diagnostic or interventional procedure or imaging findings and to observe how to communicate bad news
- To participate in and to perform under supervision at multidisciplinary paediatric conferences and paediatric tumour boards

B-I-12 UROGENITAL RADIOLOGY

Content reviewed by ESUR (European Society of Urogenital Radiology)

INTRODUCTION

The aim of this curriculum in genitourinary imaging is to ensure that the trainee develops core knowledge of the relative value of available imaging modalities with regard to normal genitourinary tract, genitourinary diseases and common genitourinary interventional procedures. This knowledge will form the basis for further training (if desired) and also provide transferable skills that will equip the trainee to work as a specialist in any branch of radiology.

Physics, contrast media and radiation protection are covered in separate sections, and therefore are not included in detail in this section, unless of particular relevance to genitourinary imaging.

KNOWLEDGE

(SEE ALSO B-I-6 GYNAECOLOGICAL AND OBSTETRIC RADIOLOGY)

- To describe normal anatomy and normal variants of the kidneys, ureters, bladder and urethra
- To describe normal anatomy and normal variants of the retroperitoneum and the male and female pelvis
- To understand the principles of renal function
- To be familiar with typical imaging features of renal parenchymal diseases, including infection and renovascular disease
- To understand the renal excretion process of contrast media and possible side effects in case of renal failure
- To understand contrast medium management in renal failure
- To be familiar with typical imaging features and with the appropriate imaging investigation algorithm of calculus disease
- To understand the imaging features of urinary tract obstruction and reflux
- To understand imaging features and to differentiate tumours of the kidney and urinary tract
- To understand the typical imaging features of renal transplants
- To understand imaging features and differential diagnoses of pathologies of the prostate, seminal vesicles and testes/scrotum
- To be familiar with urogenital emergencies including management

SKILLS

- To perform transabdominal ultrasound examinations of the urinary tract
- To perform grey-scale and Doppler ultrasound examination of the scrotum
- To perform transabdominal and transrectal ultrasound examination of the prostate
- To manage CT-urography examinations, with exact knowledge of specific post-contrast phases timing
- To plan CT examinations in patients with common disorders of the urogenital system and to adapt the examination protocol to the individual situation with a dose as low as reasonably achievable, including the decision for or against contrast administration

- To plan MRI examinations in patients with common disorders of the urogenital system and to adapt the examination protocol to the individual situation, including the decision for or against contrast administration
- To perform proper post-processing tasks for imaging studies of the urogenital system, including multiplanar reformations (MPR) and maximum intensity projections (MIP)
- To perform ascending urethrograms and micturating cysto-urethrograms under supervision

COMPETENCES AND ATTITUDES

- To justify diagnostic imaging examinations of the urogenital system
- To choose the best-suited method for evaluating disorders of the urogenital system
- To communicate with the patient in order to obtain informed consent prior to diagnostic imaging of the urogenital system
- To choose optimal imaging parameters for radiographic, ultrasonographic / Doppler-sonographic, CT and MRI examinations of the urogenital system
- To apply techniques to reduce exposure doses for radiographic and CT examinations of the urogenital system
- To design imaging protocols for CT examinations of the urogenital system
- To design imaging protocols for MRI examinations of the urogenital system
- To supervise and teach technical staff to ensure that appropriate images of the urogenital system are obtained
- To interpret and report radiographs, ultrasonographic / Doppler-sonographic examinations, CT studies and MRI examinations of the urogenital system
- To report oncological studies of the urogenital system according to international standards (RECIST, WHO) applicable to the specific situation
- To appreciate own limitations and to identify when it is appropriate to obtain assistance in interpreting and reporting images of the urogenital system
- To identify urgent and/or unexpected findings in imaging examinations of the urogenital system and to communicate these timely and properly
- To communicate with patients and their relatives in order to explain their imaging findings of the urogenital system
- To participate in and to perform under supervision at multidisciplinary conferences and tumour boards for diseases of the urogenital system
- To understand Bosniak classification
- To understand the PI-RADS scoring system
- To obtain differential diagnosis between testicular torsion and other common causes of acute scrotal pain

B-I-13 NUCLEAR MEDICINE AS BASIC TRAINING

INTRODUCTION

The aim of this curriculum in nuclear medicine (hybrid imaging) is to ensure that the trainee develops core knowledge of the relative value of available imaging modalities with regard to nuclear medicine with focus on hybrid imaging and to understand the role of these techniques within the diagnostic imaging algorithms. This knowledge will form the basis for further training (if desired) and also provide transferable skills that will equip the trainee to work as a specialist in any branch of radiology.

Recommended three-months training period by no means implies a full training in nuclear medicine.

KNOWLEDGE

- To describe basic principles of physics including the basic atomic structure, principles of radioactivity and basic of radioactive decay
- To be familiar with basic principles of the production of radionuclides, manufacturing, desirable characteristics and physiological distributions of radiopharmaceuticals and commonly used positron emission tomography (PET)-tracers
- To explain the principles of biological and effective half-life
- To understand the principles of quantification of PET studies including standardised uptake values (SUV)
- To describe the basic physical principles of nuclear medicine imaging technology, including gamma cameras, single photon emission computed tomography (SPECT) and PET
- To understand the basic physical principles of hybrid imaging, including SPECT/CT, PET/CT, and PET/MR
- To be familiar with imaging performance parameters, including uniformity of response, system sensitivity, spatial resolution, spatial linearity, count rate performance and image quality
- To understand safety aspects in nuclear medicine and hybrid imaging, including patient dosimetry, staff dosimetry, contamination, monitoring, choice of equipment, quality control and safety/risk management

SKILLS

- To observe nuclear imaging studies with gamma cameras, SPECT and PET/CT

COMPETENCES AND ATTITUDES

- To apply the appropriateness criteria and indications for nuclear medicine and hybrid imaging procedures under supervision
- To assist referring physicians in selecting the best-suited nuclear medicine or hybrid imaging examinations for common indications
- To communicate with the patient in order to inform them about the procedures and obtain informed consent prior to nuclear medicine or hybrid imaging studies
- To choose optimal imaging protocols for nuclear medicine and hybrid imaging examinations under supervision

- To apply techniques to reduce exposure doses for nuclear medicine and hybrid imaging studies under supervision
- To interpret and report common nuclear medicine and hybrid imaging studies under supervision
- To appreciate own limitations and to identify when it is appropriate to obtain assistance in interpreting and reporting nuclear medicine and hybrid imaging examinations
- To identify urgent and/or unexpected findings in nuclear medicine and hybrid imaging examinations and to communicate these timely and properly
- To communicate with patients and their relatives in order to explain their imaging findings of nuclear medicine studies under supervision
- To participate in multidisciplinary clinical reviews and tumour boards under supervision

B-I-14

RADIATION PROTECTION EDUCATION AND TRAINING**INTRODUCTION**

The aim of the curriculum in Radiation Protection Education and Training is to ensure that the trainee develops core knowledge about radiation protection. This includes an understanding of the radiation physics and the main characteristics and effects of radiation. The competences gained should provide appropriate skills for adequate dose management topics as well as for understanding and following different applicable regulatory frameworks.

KNOWLEDGE

- To list the sources and properties of ionising radiation
- To list and explain mechanisms of interaction between ionising radiation and matter/tissues
- To list and explain mechanisms of radioactive decay
- To explain the phenomena of X-ray interaction with matter and the consequences for image generation, image quality and radiation exposure
- To list and explain definitions, quantities and units of kerma, absorbed energy dose (Gy), organ and effective doses (Sv) as well as exposure rate and dose rate
- To understand the mechanism of X-ray production
- To list the components of an X-ray unit and explain the process of X-ray generation
- To explain the function of filters and diaphragms
- To list the common analogue and digital detectors, explain their function and their relative pros and cons
- To explain the role of screens (in analogue radiography) and grids and their effect on image quality and exposure
- To describe radiation effects on cells and DNA
- To describe cellular mechanisms of radiation response, repair and cell survival
- To describe radiation effects upon tissues and organs
- To explain differences in radiation response between healthy tissue and tumours as basis for radiation treatment
- To define and explain stochastic, deterministic and teratogenic radiation effects
- To describe types and magnitudes of radiation risk from radiation exposure in medicine
- To describe the basic principles of radiation protection, as outlined by the ICRP (International Commission on Radiological Protection)
- To specify types and magnitudes of radiation exposure from natural and artificial sources
- To describe concepts of dose determination and dose measurement for patients, occupationally exposed personnel and the public
- To explain the nature of radiation exposure and the relevant dose limits for the worker, including organ doses and dose limits for pregnant workers, comforters, caregivers, and the general public
- To define As Low As Reasonably Achievable (ALARA) and its applicability to diagnostic radiology settings
- To explain the concepts and tools for dose management in diagnostic radiology with regard to adult and paediatric patients
- To explain the factors influencing image quality and dose in diagnostic radiology

- To describe the methods and tools for dose management in diagnostic radiology: radiography, fluoroscopy, CT, mammography, and those for paediatric patients
- To explain the basic concepts of patient dose measurement and calculation for the different modalities in diagnostic radiology
- To describe the key considerations relevant to radiation protection when designing a diagnostic radiology department
- To have knowledge of the basic principles, opportunities and use of dose monitoring systems
- To list diagnostic procedures performed outside the radiology department with relevant radiation protection considerations
- To list expected doses (reference person) for frequent diagnostic radiology procedures
- To explain quantitative risk and dose assessment for workers and the general public in diagnostic radiology
- To define Quality Assurance (QA) in radiology, QA management and responsibilities, outline a QA and radiation protection programme for diagnostic radiology
- To list the key components of image quality and their relation to patient exposure
- To explain the principle of diagnostic reference levels (DRLs)
- To list national and international bodies involved in RP regulatory processes
- To specify the relevant regulatory framework (ordinances, directives, etc.) governing the medical use of ionising radiation in the respective country and the EU
- To specify the relevant regulatory framework governing the practice of diagnostic radiology in the respective country and in the EU
- To understand the effects of poor-quality images

SKILLS

- To apply radiation physics to optimally select the best imaging modality
- To apply radiation physics to optimise the protocols, using minimal exposure to reach the image quality level needed for the task
- To use the laws of physics to minimise scatter and optimise contrast
- To use the correct terms to characterise exposure in daily radiograph fluoroscopy and CT examinations, define organ risk and estimate the genetic and cancer risk
- To use the technical features of the specific equipment and take advantage of all quality-improving and dose-reducing capabilities while recognising the limits of the machine
- To communicate the radiation risk to the patient at an understandable level, whenever there is a significant deterministic or stochastic risk, or when the patient has a question
- To communicate with the referrer regarding justification, and, if necessary, to suggest a different test
- To apply the three levels of justification in daily practice, with respect to existing guidelines, but also to individual cases (e.g., polymorbidity)
- To optimise imaging protocols by using standard operating procedures (SOPs) and by adapting these to the specific patient's size
- To use specific paediatric protocols, by taking into consideration the physics of small size, but also the elevated risk, vulnerability and specific pathology of each age group
- To choose the best compromise between risk-benefit-ratio, image quality and radiation exposure on a case-by-case basis

- To supervise the use of personal protective equipment
- To support monitoring of the workplace and individuals
- To support exposure assessment, investigation and follow up, health surveillance, and records
- To apply and advise on the use of radiation protection measures in diagnostic radiology (radiography, fluoroscopy-intervention, CT, mammography and paediatric patients)
- To stay within guidance/reference levels in daily practice
- To set up size-specific protocols for high-dose procedures
- To set up specific protocols for low-dose CT-studies
- To estimate organ doses and effective doses for diagnostic radiology examinations, based on measurable exposure parameters (KAP, DLP)
- To apply standards of acceptable image quality
- To perform retake analyses

COMPETENCES AND ATTITUDES

- To appreciate and respect roles and responsibilities of medical physicists
- To effectively communicate and exchange critical information with medical physicists, to optimise imaging protocols and ensure the highest standards of radiation safety
- To continuously check image quality in order to recognise and correct technical defects
- To demand the best in image quality, technical innovation and exposure reduction for the lowest cost
- To coordinate the commissioning of new equipment with the other members of the core team (radiographer, medical physicist)
- To develop an organisational policy to keep doses to the personnel as low as reasonably achievable (ALARA)
- To avoid unnecessary radiation exposure during pregnancy (warning signs, questionnaire) by optimising the technique (size and positioning of the x-ray field, gonad shielding, tube-to-skin distance, correct beam filtration, minimising and recording the fluoroscopy time, excluding non-essential projections, avoiding repeat radiographs)
- To find and apply the relevant regulations for any clinical situation in radiology
- To choose the best equipment for the patient spectrum based on the resources available
- To take responsibility for choosing the best imaging modalities for the individual patient (radiography, CT, alternatives such as ultrasound or MRI) by taking into consideration the risk of the disease, patient, age and size, the dose level of the procedure and exposure of different critical organs
- To consult both the patient and staff on pregnancy-related concerns in radiation protection
- To take responsibility for patient dose management in different imaging modalities
- To advise patients on the radiation-related risks and benefits of a planned procedure
- To take responsibility for the justification of radiation exposure for every individual patient, with special consideration for pregnant patients
- To take responsibility for choosing and performing the diagnostic procedure with the lowest dose for a given referrer's request
- To take responsibility for optimising the radiographic technique/protocol used for a given diagnostic procedure based on patient-specific information

- To take responsibility for applying the optimal size-adapted and problem-adapted individual protocol for high-dose procedures (CT, fluoroscopy-intervention)
- To supervise quality control procedures on all equipment related to patient exposure
- To take responsibility for the establishment of formal systems of work (Standard Operating Procedures) for radiation protection
- To take responsibility for organisational issues and implementation of responsibilities and local rules in regard to radiation protection
- To take responsibility for compliance with regulatory requirements concerning occupational and public radiation exposures
- To take responsibility for compliance with ALARA principles concerning occupational and public radiation exposures
- To take responsibility for conforming with patient protection regulations (including diagnostic reference levels, where applicable)

B-I-15

PRINCIPLES OF IMAGING TECHNOLOGY & MOLECULAR IMAGING

INTRODUCTION

The aim of the curriculum in Principles of Imaging Technology & Molecular Imaging is to ensure that the trainee develops core knowledge pertaining to radiography, computed tomography (CT), magnetic resonance imaging (MRI), ultrasound, contrast media/agents, signal processing and post-processing as well as molecular imaging. This knowledge will provide transferable skills that will equip the trainee to work as a specialist in any branch of radiology.

KNOWLEDGE

RADIOGRAPHY

- To explain the relative value of a radiographic examination for the various organ systems and indication
- To have an in-depth understanding of the physical basis of image formation of conventional X-ray
- To explain the concept of electromagnetic waves
- To describe X-ray production, with emphasis on the effects on dose and image quality of altering kV and mA and on the trade-off between diagnostic quality imaging and minimising the effective dose
- To describe the interaction between X-rays and matter
- To describe the structure, role and function of filters, collimators and grids
- To explain the principles of radiographic image acquisition
- To explain the principles of digital image acquisition / digital radiography
- To list and describe the factors affecting image quality in conventional and digital radiography
- To describe the indications for the use of X-ray contrast media in the study of various organs / organ systems
- To describe the principles of fluoroscopy
- To describe the indications for fluoroscopy including the principles of contrast application and to list optimised protocols
- To list techniques to enhance image quality and to reduce radiation in fluoroscopy
- To describe the principles of soft tissue radiography, e.g., in mammography
- To explain the principles of specimen radiography
- To have an in-depth understanding of dosimetry
- To have an in-depth understanding of radiation biology

COMPUTED TOMOGRAPHY - CT

- To explain the relative value of a CT examination for the various organ systems and indications
- To have a good understanding of the physical basis of image formation of computed tomography and of the physics of helical and multidetector CT
- To have a basic understanding of dual-source CT
- To have a basic understanding of photon-counting CT
- To list the major sources of artefacts in CT
- To define the scale of Hounsfield units and to explain the principle of window centre and width
- To list the optimal setting of window centre and width for various organs and tissues
- To list the normal levels of attenuation (in HU) for the various organs and pathological processes in the body
- To describe the principles of optimising sequence protocols for a variety of CT scanner types
- To understand the principles of perfusion imaging with CT
- To understand the principles of CTA protocols, including contrast materials used and reconstruction techniques
- To define CT protocols for the various organs and pathological processes in the body
- To explain the principles of reconstruction algorithms and kernels
- To describe the indications for the use of CT contrast media in the study of various organs / organ systems
- To have a good understanding of CT-dosimetry

MAGNETIC RESONANCE IMAGING - MRI

- To explain the relative value of an MRI examination for the various organ systems and indications
- To explain the fundamentals of MR physics
- To have an appreciation of the hardware associated with an MRI system
- To have a basic understanding of the physical basis of image formation in MRI
- To explain the principles of pulse sequences and relaxation times
- To explain the principles of spin echo and gradient echo sequences and their fast variants
- To describe the principles and main diagnostic applications for the most commonly used sequences in MRI, including T2-weighted sequences, T1-weighted sequences, inversion recovery sequences, and T2*- / susceptibility weighted sequences
- To describe the typical appearance of tissues, organs and pathological processes on these MR sequences
- To understand the sequence technology for MR angiography (MRA) including time of flight (TOF), phase contrast (PC), other non-(exogenous) contrast-enhanced MRA techniques and contrast-enhanced MRA
- To discuss the advantages and disadvantages of different contrast agents used for MRA
- To discuss the differences between the various MRA techniques
- To discuss advantages and disadvantages of MRA compared with other techniques
- To explain the principles of dynamic contrast-enhanced (DCE) MRI
- To explain the principles of diffusion-weighted imaging (DWI) and diffusion tensor imaging (DTI)
- To have an appreciation of the principles of functional MRI (fMRI) using the BOLD contrast mechanism
- To outline the principles of spectroscopy using ^1H
- To describe typical artefacts on MRI and to discuss their respective causes and solutions where possible

- To describe the indications/contra-indications for the use of MR contrast agents in the study of various organs / organ systems
- To explain the contraindications to MRI and how to conduct MR examinations of patients with MR conditional active or passive implants
- To have detailed appreciation of the safety issues associated with MRI with regard to both patients and staff

ULTRASOUND

- To explain the relative value of an ultrasound examination for the various organ systems and indications
- To describe the nature of ultrasound waves, their propagation, velocity, intensity and the equations that describe them
- To describe the principles of acoustic impedance and to list the tissue properties that determine it
- To describe the frequency of transmission to achieve satisfactory imaging
- To describe the physical principles of the piezoelectric phenomenon
- To list factors that determine the resonance frequency of the piezoelectric element
- To explain the principles of continuous and pulsed emission ultrasound
- To list the factors that focus and unify the ultrasound beam
- To describe the differences between the A, B and TM modes of ultrasound
- To explain the principles of spatial and temporal resolution of ultrasound images as applied to good image formation
- To explain the principles of the Doppler effect and the application of angled beam and direction of flow
- To describe the application of pulsed and continuous wave Doppler and spectral waveform analysis
- To describe the thermal and mechanical biological effects of ultrasound waves, including production of the cavitation phenomenon
- To describe the different types of transducers in ultrasound imaging
- To list the appropriate transducers according to the organs imaged
- To explain the relative value of transcutaneous vs. endoluminal sonography
- To describe criteria for a good ultrasound image
- To describe the major artefacts on ultrasound imaging including reflection, diffusion and speckle and to list their respective causes
- To describe the indications for the use of ultrasound contrast media in the study of various organs / organ systems

CONTRAST MEDIA /AGENTS

- To understand the molecular structure, pharmacology, classification, dose and side effects of all radiographic, MRI and ultrasound contrast media
- To explain the principles of contrast ultrasound media and the relation between the ultrasound beam and microbubbles
- To explain the principle of ionic and non-ionic contrast agents

- To describe the physiological principles, physical properties, toxic effects, anaphylactoid reaction and biological effects of iodinated contrast media
- To describe the physiological principles, physical properties, toxic effects, anaphylactoid reaction and biological effects of MRI contrast agents
- To outline the best contrast material and its optimal use according to the imaging technique and the clinical problem
- To describe the various timing phases of contrast media application and their respective values according to the clinical problem
- To describe the fundamentals of intravascular bolus kinetics and constant rate input
- To describe the physiology of renal excretion of contrast medium
- To describe enhancement curves within renal compartments after injection of contrast agents
- To list concentrations and doses of contrast agents used intravenously
- To define the nephrotoxicity of contrast media
- To list risk factors of contrast media nephrotoxicity
- To identify patients at risk of contrast media nephrotoxicity
- To list methods to reduce the risk of contrast nephrotoxicity
- To describe precautions in diabetics taking metformin and requiring intravascular administration of contrast media
- To list measures to reduce the risk of contrast media nephrotoxicity
- To have an in-depth understanding of nephrogenic systemic fibrosis (NSF) including the definition of NSF, the clinical features and the risk factors
- To describe the use of Gadolinium-based contrast agents in patients at risk

SIGNAL PROCESSING AND POST-PROCESSING

- To have a basic understanding of the principles of signal processing
- To describe the principles of linear systems including convolution, Fourier transformation, Nyquist, image restoration and deconvolution
- To describe the principles of image display
- To have a good understanding of image quality, including noise, contrast, resolution, and noise amplification during processing
- To be familiar with the principles of quantification including ROI analyses, time-activity curves and factorial analysis
- To understand the principles of image processing including edge, enhancement, smoothing, segmentation, image reconstruction, image fusion, registration, and display

MOLECULAR IMAGING

- To have an understanding of basic principles of cell biology and biochemistry including DNA and RNA activity, metabolism, apoptosis and hypoxia
- To have a basic understanding of stem cell migration and stem cell differentiation
- To understand the basic principles of the most commonly used molecular imaging methods, including nuclear medicine (PET, micro-PET, micro-SPECT) and optical imaging (fluorescence, bioluminescence)
- To have a basic understanding of principles of targeted contrast agents
- To have a basic understanding about demand on pharmacology and pharmacokinetics for a diagnostic probe

- To list the most common molecular targets for imaging
- To list the most commonly used tracers in molecular imaging
- To have an appreciation of the methods of molecular imaging, including its potential application to oncology, cardiovascular imaging, neurology and drug delivery
- To have a basic understanding of the strategies of gene therapy, including gene replacement, gene repair and silencing, and of cell therapy
- To have an understanding about chemistry and biotechnology methods relevant for probe development
- To understand PET image analysis and data processing
- To have an appreciation of hybrid imaging, e.g., PET/CT, PET/MR

SKILLS

- To choose the optimal contrast medium for common clinical indications for all types of imaging studies
- To be able to perform an emergency treatment for adverse reactions to contrast media when required
- To identify patients at risk of contrast media nephrotoxicity
- To take measures to reduce the risk of contrast nephrotoxicity
- To take precautions in diabetics taking metformin and requiring intravascular administration of contrast media
- To take measures to reduce the risk of contrast media nephrotoxicity
- To identify patients at risk to develop NSF
- To choose optimal exposure parameters for radiographic imaging
- To choose optimal acquisition parameters for common CT applications
- To choose optimal MR sequences for common indications for MRI
- To choose the appropriate ultrasound transducer according to the organ imaged
- To choose optimal imaging parameters in ultrasound and Doppler sonography
- To obtain Doppler spectra on the various vessels of the body

COMPETENCES AND ATTITUDES

- To choose optimal imaging parameters for all imaging technologies
- To make informed purchasing decisions for imaging equipment for a radiological department respecting imaging technology, radiation protection, budget restrictions and legal considerations
- To have an understanding of the procedures, documentation and regulations regarding European tenders for purchasing within the field of radiology
- To devise strategies to reduce artefacts on conventional radiography, fluoroscopy, CT, MRI and ultrasound
- To appreciate the effect of the properties of the machine/scanner on image quality and to optimise the image quality for the machine/scanner available for all common imaging indications
- To appreciate the effect of the properties of image recording and display and to optimise the image quality in the available setting for all common imaging indications
- To appreciate the impact that image quality has on clinical performance and to enhance image quality to the best extent possible
- To confidently devise and conduct quality assurance programmes

B-I-16

PRINCIPLES OF MEDICAL IMAGING INFORMATICS

Content reviewed by EuSoMII (European Society of Medical Imaging and Informatics)

INTRODUCTION

The aim of this curriculum in Medical Imaging Informatics is to ensure that the trainee develops core knowledge of the different aspects of computer science and information technology in the field of medical imaging. This knowledge will form the basis for further training in this domain (if desired) and provide transferable skills that will equip the trainee to work as a specialist in any branch of radiology.

KNOWLEDGE

Knowledge of radiology workstations, networks, RIS, PACS and EPR

- To have a basic knowledge of computer networks and cloud services, including the relevant security issues
- To have a basic knowledge of different options for storage of digital data
- To understand basic components of a radiology workstation (both hardware and software)
- To have a basic knowledge of monitor and lightning requirements for different imaging modalities
- To understand basic techniques of Picture Archiving and Communication Systems (PACS) and Radiology Information Systems (RIS)

Knowledge of standards and codes

- Basic knowledge of DICOM and HL7. To be aware of the role of IHE in using these standards
- Basic knowledge Electronic Patient Records (EPR)
- Knowledge of standards and coding systems (RadLex, LOINC, etc.)

Knowledge of radiological software applications

- To have a basic knowledge of image (post-) processing (including multiplanar reformation, MIP and MinIP, volume rendering) and 3D-printing
- To have knowledge of the radiation dose index terminology (such as CTDIvol, DLP, DAP, and DRL)
- Understand the basics of automated dictation systems and speech recognition
- To have a basic knowledge of Structured Reporting (SR)
- To have a knowledge of the role and utility of social networks in radiology communication
- To have a basic knowledge of Hospital Information Systems (HIS), Electronic Medical Records (EMR) and their relation to information systems used in Radiology
- To have a knowledge of web-portals for patients
- To know the basic aspects of teleradiology and telemedicine

- Have a basic knowledge of Clinical Decision Systems (CDS)
- To understand the functioning and basic principles of Artificial Intelligence (AI) tools
- To understand the basic principles of Machine Learning and Deep Learning

SKILLS

- To develop general computer skills as user
- To know how to use electronic communication skills
- To know how to use computers for clinical presentations
- To know how to use Structured Reporting (SR) applications
- To know how to use RIS and HIS for accessing patients' clinical data and prior examinations
- To know how to use advanced post-processing (e.g., 3D reconstruction) functions
- To ensure that the PACS monitor is displaying the data appropriately
- To know how to communicate with the technological support when systems fail (diagnostic equipment, workstations, servers, RIS/PACS)
- To know how to route studies and to perform manual sending of images
- To know how to use a basic statistical software, a dose tracking systems and a business intelligence tool
- To be able to use voice recognition and Clinical Decision Support (CDS) systems

COMPETENCES AND ATTITUDES

- To know how to use informatics tools to facilitate and improve image display, interpretation and diagnosis
- To know how to use informatics tools in the benefit of the patients
- To know how to use informatics tools to provide an actionable report
- To know how to use informatics tools to optimise clinical protocols and improve clinical workflows for radioprotection purposes and behind

B-I-17 COMMUNICATION AND MANAGEMENT

INTRODUCTION

The aim of the curriculum in Communication and Management is to ensure that the trainee develops core knowledge pertaining to radiological reporting as well as different medico-legal aspects of the radiological practice. The competences gained should also allow the trainee to confidently communicate, in particular with the patients, but also with referring colleagues and all members of multidisciplinary care teams, and to engage into teaching activities.

KNOWLEDGE

- To be familiar with the principles of communicating bad news
- To have an in-depth understanding of the nature, structure and medico-legal aspects of radiological reporting
- To understand the importance of timely communication with referring doctors regarding imaging reports
- To understand the important role of the radiologist in multidisciplinary meetings and tumour boards
- To know the basic principles of communication and active participation in multidisciplinary meetings, including an appreciation of the transfer of knowledge, demonstration of imaging findings, and awareness of treatment consequences
- To understand the basic didactic principles of teaching radiology
- To describe the principles of administration and management as applicable to a clinical imaging department with multidisciplinary staff and high-cost equipment
- To be familiar with the procedures, legalities, critical evaluation processes and priorities required for systems purchase
- To understand the principles of teleradiology and its potential role and legal implications
- To understand the methodology and principles of the clinical audit with honesty and integrity, full agreement, and confidentiality
- To understand the concept of measured performance and the comparison with target standards
- To interpret the results of audit measurements, the process of implementing change and the re-measurement of performance
- To understand the limitations of the selection of appropriate target standards
- To describe relevant country-specific legal implications of audits
- To appreciate the concepts of consensus statements from learning bodies and the methodology for sourcing them
- To understand the medico-legal implications of the radiological practice
- To understand the concept of perceptual errors
- To be aware of the risk and consequences of missed imaging diagnoses
- To be familiar with the concepts of uncertainty and error in radiological practice
- To have an in-depth understanding of more common radiological pitfalls
- To be familiar with concepts to minimise radiological risk
- To describe the concept of hindsight bias

- To understand the importance of the comparison with previous examinations
- To be aware of the specific liabilities relating to screening
- To have a basic understanding of health economics

SKILLS

- To formulate a comprehensive radiological (structured) report according to accepted standards
- To use an adequate terminology for the respective clinical question
- To perform cost-benefit and cost-efficiency evaluations for common imaging strategies
- To perform audits of structure, process and outcome
- To teach undergraduate students or other trainees relevant radiological knowledge and skills

COMPETENCES AND ATTITUDES

- To relate to the patient and their families with respect, honesty and confidentiality
- To be able to explain diagnostic imaging examinations and interventional procedures to the patient and to obtain informed consent
- To be able to explain examination results to patients and/or their families when appropriate
- To properly communicate with referring colleagues
- To distinguish between routine methods of communication and the necessity for immediate reporting of emergency, life-threatening or unexpected findings
- To timely and adequately communicate urgent or unexpected findings

B-I-18

RESEARCH AND EVIDENCE-BASED MEDICINE**INTRODUCTION**

The aim of the curriculum in Research and Evidence-Based Medicine is to ensure that the trainee develops core knowledge about planning, conducting and presenting of research studies in a methodologically sound manner. This includes understanding basic elements of scientific methods and evidence-based medicine as well as gaining competences pertaining to data analysis and use of statistics. This knowledge will provide skills that will allow the trainee to critically evaluate published primary and secondary radiological studies across various branches of radiology.

KNOWLEDGE

- To understand the basic elements of scientific methods and evidence-based medicine
- To have an in-depth understanding of design and data analysis for technical and diagnostic performance studies, including the influence of disease prevalence and spectrum on sensitivity, specificity, accuracy, and predictive values as well as the use of ROC analysis in radiological studies
- To understand the statistical principles essential for critical evaluation of published radiological primary and secondary studies (i.e., meta-analyses, cost-effective analyses)
- To understand the basic statistics of randomised controlled trials
- To understand the principles and practice of clinical audit
- To have a basic understanding of didactic methods to teach radiology

SKILLS

- To present studies from the radiological literature in departmental meetings
- To perform basic biostatistical tests relevant to the radiological literature
- To perform a focused literature search of the relevant radiological literature
- To perform clinical audit in a radiological department

COMPETENCES AND ATTITUDES

- To appraise the relevant radiological literature in a critical manner
- To plan and conduct research studies under supervision in a methodologically sound manner
- To understand the value and methods of evolving imaging technologies

SUMMARY OF LEVEL I KNOWLEDGE

The European Training Curriculum for Radiology is designed to provide a valuable template for training radiologists and to enhance the quality of care for patients throughout Europe. As such, it outlines a 5-year radiology training period with Level I covering the first 3 years.

After successfully completing Level I of the European Training Curriculum the trainee will have obtained interrelated knowledge from different radiology subspecialties that in turn forms a basis for future training and provides transferable skills that will equip the trainee to work as a specialist in any branch of radiology as well as managing emergency cases.

The main knowledge components of Level I consist of fundamentals of undertaking and interpreting a wide range of imaging techniques and disease manifestations. Accordingly, Level I of the European Training Curriculum equips the trainee with core knowledge pertaining to Breast Radiology, Cardiac and Vascular Radiology, Chest Radiology, Emergency Radiology, Gastrointestinal and Abdominal Radiology, Gynaecological and Obstetric Radiology, Head and Neck Radiology, Interventional Radiology, Nuclear Medicine as Basic Training, Musculoskeletal Radiology, Neuroradiology, Paediatric Radiology, Urogenital Radiology, Radiation Protection Education and Training, Principles of Imaging Technology and Molecular Imaging, Principles of Medical Imaging Informatics, Communication and Management and Research and Evidence-Based Medicine.

Apart from the knowledge of normal imaging anatomy and physiology and a wide range of radiological skills, including the performance of a variety of procedures from different radiological subspecialties, after completing Level I trainees will acquire the necessary knowledge of basic sciences, the physical basis of image formation in all imaging techniques, picture archiving and communication systems (PACS), radiology and hospital information systems, quality control and quality management, radiation physics, radiation biology, radiation protection, anatomy, physiology, cell biology and molecular structure, biochemistry and techniques related to radiological procedures.

Level I will also equip the trainees with the knowledge of the pharmacology and application of contrast media and the treatment of adverse reactions to them, a basic understanding of computer science, the fundamentals of clinical research as well as statistics and evidence-based medicine as applied to radiology.

Additionally, trainees will be provided with knowledge, skills, competences and attitudes related to different aspects of emergency radiology.

B-II:
**LEVEL II
TRAINING
(YEARS 4-5)**

LEVEL II TRAINING (YEARS 4-5)

INTRODUCTION

Level II Training should be interpreted as a continuum of radiology training. During these two years it is envisaged that the trainee should spend approximately 50% of the time in general radiology, with 50% exposure to a maximum of two subspecialty areas. One of these subspecialty areas may remain general radiology.

The curricular content for Level II Training comprises the following subject areas:

B-II-1 Breast Radiology

B-II-2 Cardiac and Vascular Radiology

B-II-3 Chest Radiology

B-II-4 Emergency Radiology

B-II-5 Gastrointestinal and Abdominal Radiology

B-II-6 Gynaecological and Obstetric Radiology

B-II-7 Head and Neck Radiology

B-II-8 Interventional Radiology

B-II-9 Musculoskeletal Radiology

B-II-10 Neuroradiology

B-II-11 Oncologic Imaging

B-II-12 Paediatric Radiology

B-II-13 Urogenital Radiology

B-II-14 Medical Imaging Informatics

B-II-1 BREAST RADIOLOGY

Content reviewed by EUSOBI (European Society of Breast Radiology)

INTRODUCTION

In Level II an in-depth extension of knowledge and skills, based on the experience received in Level I will be expected. In particular:

- Screening, the epidemiology of breast cancer and risk categorisation, particularly with regards to breast density
- Newer technologies such as tomosynthesis and more advanced applications of MRI including diffusion-weighted imaging
- Staging of breast cancer and the role of imaging
- Imaging of breast cancer recurrence
- Trainees are also expected to have built on the skills learnt in Level I to be able to work more independently in a breast clinic, supporting clinicians during the diagnosis and treatment of a variety of breast lesions. Breast interventional procedures should be able to be performed independently including US and stereotactic-guided biopsy and breast localisation procedures
- Competence is also further assessed at Level II by means of reporting (under supervision) of at least 800 mammograms, 500 ultrasound, 50 breast MR studies and 50 interventional procedures during the two years

KNOWLEDGE

- To have an understanding of epidemiological data regarding breast cancer
- To identify major risk factors of breast cancer, including familial-genetic predisposition and previous thoracic radiation therapy
- To understand principles of risk stratification and the indications for genetic counselling
- To appreciate the principles and objectives of population screening
- To be aware of the masking effect of breast density determining a reduced sensitivity of mammography
- To know the relative role of breast density as a risk factor for breast cancer
- To describe the structure and management of a national or regional screening programme (if it exists)
- To identify the risks and benefits of screening to the population and the individual, including those related to subject age, family and personal history
- To understand screening theory and to describe lead time bias, length bias, survival versus mortality rates, prevalence versus incidence screening, definition of lead time and interval cancer rate, overdiagnosis and overtreatment
- To describe the European guidelines for breast cancer screening and diagnosis (<http://www.euref.org/european-guidelines>)

- To know the potential of tomosynthesis in the screening setting for increasing the detection rate and reducing the recall rate
- To describe the principles and techniques used in screening audit, including the concepts of prevalent and incident cancer rates, recall rates and interval cancers
- To analyse controversies regarding mammographic screening and related research, including overdiagnosis / overtreatment
- To describe normal embryology, anatomy and physiology of the breast, axilla and associated structures and to particularly understand changes due to age, lactation, hormonal status, hormone replacement therapy, surgery (including breast reduction / augmentation as well as oncoplastic reconstruction), radiotherapy etc.
- To have an in-depth understanding of benign diseases of the breast and of how these diseases manifest, both clinically and on imaging
- To have an in-depth appreciation of borderline or high-risk breast lesions (those defined to imply an uncertain potential for malignancy) and of their clinical and pathological significance
- To have an in-depth understanding of malignant diseases of the breast, axilla and associated structures, of genetic subtypes, of histological prognostic factors and of the TNM classification
- To be familiar with cytological and pathological reporting of breast diseases
- To be familiar with the biomolecular classification of breast cancer and to be able to understand the imaging implications of that classification
- To be aware of methods of radiologic-pathologic correlation of breast lesions
- To be familiar with the principles and indications for breast-conserving surgery and sentinel node biopsy
- To describe the indications for neoadjuvant chemotherapy and to understand the clinical and imaging evaluation of response to treatment
- To be familiar with adjuvant therapy options for breast cancer and with methods for surveillance after treatment
- To be familiar with radiation therapy options including methods for partial breast irradiation as well as with typical radiological findings associated with those therapies
- To have an understanding of the radiological methods for evaluating lesion tumour extent and searching for additional ipsilateral malignant lesions or contralateral malignant lesions, including potential advantages and disadvantages of preoperative MRI
- To have an understanding of extramammary staging of breast cancer and evaluation of distant metastases
- To be aware of minimally invasive therapy options for distant metastases
- To appreciate imaging appearance of local recurrence of breast cancer
- To understand the clinical management and radiological evaluation of patients presenting with a palpable breast mass, breast pain, breast trauma, inflammatory findings, nipple discharge, nipple or skin retraction, nipple thickening and axillary adenopathy
- To understand the imaging work-up and main pathological conditions that can be detected in male patients, children and adolescents, and in pregnant and lactating women
- To have an in-depth understanding of the planning, implementation, supervision and interpretation of all imaging techniques used in breast imaging, as well as potential complications, including indications and contraindications to the various imaging methods
- To have an in-depth understanding of standardised lexicon and categories of breast imaging reporting with reference to lesion, breast or patient (ACR BI-RADS® or other standardised classification methods)
- To have an understanding of tomosynthesis in the clinical setting
- To have an understanding of contrast enhanced mammography, including its indications and contra-indications

- To have a basic understanding of therapeutic imaging-guided techniques (radiofrequency ablation, focused ultrasound, cryoablation) breast cancer and benign breast diseases
- To have a basic understanding of advanced applications of ultrasound including elastography and contrast enhanced techniques
- To have a basic understanding of advanced applications of MRI including diffusion weighted imaging and spectroscopy
- To appreciate the central role of the multidisciplinary team in planning investigations, treatment and in outcome review for breast cancer patients, being informed about recommendations of the European Parliament in favour of the breast unit model for treating breast cancer
- To have an in-depth understanding of the communication principles of breaking news and techniques and skills to perform this well
- To have some understanding of legal liability in breast imaging

SKILLS

- To take a detailed history of patients in regard to disorders of the breast and relevant risk factors
- To perform radiologic-pathologic correlation of breast lesions
- To supervise the imaging quality of the radiography of surgical specimens and communicate with the surgeon accordingly
- To participate in double reading of screening examination discussing cases of disagreement and getting a feedback after final decision and/or final assessment after recall (if a screening programme exists)
- To perform fine needle aspiration at least of cysts which require treatment aspirations
- To perform image-guided fine needle aspiration cytology under ultrasound guidance
- To perform image-guided core needle and vacuum-assisted biopsy under ultrasound, mammographic-stereotactic guidance and MRI guidance
- To perform image-guided localisation
- To perform abscess management

COMPETENCES AND ATTITUDES

- To choose the best-suited method for evaluating disorders of the breast for a variety of clinical indications
- To justify and optimise all relevant diagnostic imaging examinations and/or interventional procedures of the breast, including minimisation of x-ray exposure in mammography and choice of optimal imaging parameters for mammography, ultrasound and MRI of the breast
- To confidently judge the quality of the imaging examinations in breast imaging and to devise strategies to improve image quality
- To supervise and teach technical staff to ensure that appropriate images of the breast are obtained
- To interpret and report mammograms, breast ultrasound and breast MRI examinations using a standardised diagnostic categorisation system such as the ACR Breast Imaging Reporting and Data System (BI-RADS®); this competence should be acquired by means of performance/reporting (under supervision) of at least 800 mammograms, 500 ultrasound, 50 breast MR studies and 50 interventional procedures during the two years
- To communicate with patients and their relatives in order to explain their imaging findings in disorders of the breast
- To communicate with the patient in order to obtain informed consent prior to interventional procedures of the breast
- To appreciate own limitations and to identify when it is appropriate to obtain assistance in interpreting and reporting images of the breast

- To appreciate and respect the roles and responsibilities of all other members of the breast imaging team, e.g., clerical officers, radiographers, nurses, support staff, secretaries
- To appreciate and respect the roles and responsibilities of all other members of the multidisciplinary breast care team, being an integral part of the team in planning investigations, treatment and in outcome review
- To present at multidisciplinary conferences and tumour boards for diseases of the breast

B-II-2 CARDIAC AND VASCULAR RADIOLOGY

Content reviewed by ESCR (European Society of Cardiovascular Radiology)

INTRODUCTION

In Level II the trainee should, in addition to the knowledge, competencies and skills acquired in the first 3 years of training, have in-depth knowledge of the following:

- The pathophysiology of congenital heart disease and the standard treatments available
- The pathophysiology of ischaemic heart disease and an understanding of the management options
- The pathophysiology of acute and chronic non-ischaemic acquired heart disease including valvular heart disease, myocarditis and cardiomyopathies
- Trainees should be able to supervise and perform more advanced cardiac imaging techniques including stress cardiac MRI and advanced cardiac ECG-gated techniques (including heart rate control)
- Trainees should be able to monitor and treat patients during advanced cardiac imaging procedures and have knowledge of appropriate cardiac medications and management of complications

KNOWLEDGE

ANATOMY & NORMAL VARIANTS

- To have an in-depth knowledge of cardiovascular anatomy in CT, including coronary anatomy according to the AHA classification
- To be familiar with most common anatomical variants and anomalies in coronary anatomy
- To distinguish malignant from benign coronary variants
- To have an in-depth knowledge of cardiovascular anatomy in MRI, including vascular territories according to the AHA classification
- To understand the normal interaction of the right and left heart in health and disease

CONGENITAL

- To describe basic imaging features and basic clinical features of most common congenital heart disease including neonatal heart disease, congenital heart disease in childhood and adolescence, and adult congenital heart disease (ACHD)
- To know about clinical and imaging features of intra-and extracardiac shunts
- To describe the imaging features of congenital vascular anomalies of the cardiovascular system

IMAGE ACQUISITION AND POST-PROCESSING

- To have an in-depth knowledge of the indications, contraindications and potential hazards (especially radiation hazards) of procedures and techniques relevant to cardiovascular disease
- To know the indications and contraindications for medications before or during cardiac imaging (beta-blockers, nitroglycerin, adenosine, regadenoson, etc.)
- To describe the role of alternative cardiac assessment tools, including SPECT, PET, stress exercise test, echocardiography
- To describe the principles, uses and limitations of nuclear cardiac imaging
- To describe the principles, uses and limitations of vascular imaging in cardiovascular disorders
- To describe the principles, uses and limitations of cardiac stress testing including exercise stress testing
- To describe the principles of cardiac CT acquisition
- To describe the principles of ECG gating for cardiac CT and MRI
- To describe contrast media injection parameters and bolus timing as it pertains to cardiac and vascular CT and MRI
- To understand and confidently use cardiac imaging planes, multiplanar reconstructions (MPR), maximum intensity projection (MIP) and volume rendering principles as they apply to cardiac CT and MRI
- To describe the principles and techniques of coronary calcification scoring (calcium scoring)
- To understand the epidemiological implications of coronary calcification scoring
- To use tissue characterisation sequences at cardiac MRI
- To understand the necessary imaging prerequisites and possible risks of any MRI investigation in patients with active and passive cardiovascular implants
- To know methods to limit or reduce CT and MR artifacts related (e.g., cardiac motion, breathing, devices and leads)

CORONARY ARTERIES AND MAJOR ARTERIES

- To describe the imaging features and basic clinical features of coronary artery disease, including acute and chronic coronary syndromes, myocardial ischaemia, myocardial infarction, MINOCA, post myocardial infarction syndromes, hibernating /stunned myocardium, ventricular (pseudo) aneurysms, common and unusual causes of coronary artery disease including various forms of arteritis
- To describe the imaging presentations of atherosclerosis, including coronary calcification and high-risk plaque features on coronary CTA
- To have a basic pathological and pathophysiological understanding of acquired cardiovascular disease
- To describe the manifestations of cardiovascular disease, as demonstrated by radiography, ultrasound, CT, MRI, angiography and radionuclide investigations
- To describe the differential diagnosis relevant to clinical presentation and imaging features of cardiovascular disease
- To describe the imaging features and basic clinical features of diseases of the major vessels, including aortoiliac aneurysm, popliteal artery aneurysms, acute and chronic aortic dissection (including classification), Marfan's syndrome and vasculitides
- To describe atherosclerotic disease of the carotid arteries including grading of carotid artery stenosis by ultrasound, CTA and MRA
- To describe the imaging features and basic clinical features of diseases of the visceral arteries including acute

and chronic mesenteric ischaemia

- To describe the imaging features and basic clinical features of peripheral arterial occlusive disease, including the Rutherford, Fontaine and TASCII classification, critical limb ischemia, peripheral embolic disease and entrapment syndrome
- To describe the imaging features and basic clinical features of thoracic outlet syndromes
- To describe WHO groups, imaging features and basic clinical features of pulmonary hypertension

MYOCARDIUM, PERI- AND ENDOCARDIUM, HEART VALVES

- To describe the CT- and MRI imaging features and basic clinical features of cardiac tumours including intracardiac tumours primary cardiac tumours (myxomas, haemangiomas, sarcomas) and secondary / metastatic cardiac tumours, and to differentiate them from cardiac thrombus and other cardiac mass mimickers
- To describe the imaging features and basic clinical features acute myocarditis and cardiomyopathies
- To understand the phenotypic approach to cardiomyopathies and their morphological and functional assessment
- To identify cardiovascular involvement in systemic diseases (sarcoidosis, amyloidosis, connective tissue diseases etc.)
- To understand the differing physiology of pericardial constriction and restrictive cardiomyopathy
- To describe age- and gender-related cardiac syndromes, including sudden-cardiac death syndromes in young men
- To describe the imaging features and basic clinical features of heart valve disease including rheumatic or post-rheumatic valve disease, stenosis and incompetence of cardiac valves, endocarditis, sub- and supra-avalvular disease, subvalvular apparatus disease
- To describe the pretreatment requisites in case of planned cardiovascular surgery (aortic calcifications, vascular access, relevant anatomic and structural relations)
- To describe the imaging features and basic clinical features of pericardial disease including acute and chronic pericarditis and malignant cardiac disease
- To describe the imaging features and basic clinical features of athlete's heart
- To have a knowledge of the clinical aspects of cardiac disease including pathophysiological and biochemical correlates
- To describe the principles and practice of screening techniques and risk factors in cardiac disease

POST-PROCEDURAL CARDIAC AND VASCULAR RADIOLOGY

- To differentiate normal from pathologic conditions after cardiovascular procedures
- To describe the role of the varying treatments available for both congenital and acquired cardiac disease, including coronary artery disease and valvular disease
- To have knowledge of common procedural techniques, materials and their radiological appearances and to differentiate those from complications
- To describe the typical imaging features and basic clinical features after bypass grafts, stenting, valve replacement, aortic surgical and interventional endovascular procedures, ventricular surgery, pericardiectomy
- To describe the typical imaging features and the most common treatment-related complications (endoleaks, infections) after aortic stentgraft implantation
- To classify endoleaks after endovascular aortic repair

- To describe the typical imaging features and basic clinical features after peripheral bypass graft surgery, peripheral stent placement and surgical patch placement
- To describe the pathophysiology, differential diagnosis and treatment of femoral artery pseudoaneurysm formation following invasive cardiovascular procedures

SKILLS

- To prepare a patient for cardiac CT including indication, venous access and heart rate control
- To choose optimal acquisition parameters for cardiac CT
- To choose optimal post-processing tools for cardiac and vascular CT
- To prepare a patient for cardiac MRI including indication, venous access and medication (e.g., stress testing)
- To choose optimal acquisition parameters for cardiac MRI
- To apply ECG gating for cardiac CT and MRI
- To plan perform an optimal contrast injection protocol and bolus timing for cardiovascular CT and MRI
- To handle and limit CT artifacts
- To confidently perform and coronary artery and aortic valve calcification scoring
- To manage procedural complications in the diagnosis and treatment of cardiovascular disease, including side effects and adverse reactions to medications used before or during imaging
- To manage patients undergoing stress testing for cardiac imaging
- To confidently perform ultrasound examinations of arteries and veins
- To independently perform post-processing tasks for cardiac and vascular imaging studies, including multiplanar reformations (MPR), maximum intensity projections (MIP), minimum intensity projections (MinIP), volume rendering tools (VRT), MRI volumetry and flow measurements, and vessel analysis tools
- To perform and report dynamic examinations to rule out or diagnose thoracic outlet syndromes and entrapment syndromes

COMPETENCES AND ATTITUDES

- To confidently justify diagnostic imaging examinations (including CT and MRI) of the cardiac and vascular systems
- To confidently choose the best-suited method for evaluating disorders of the cardiac and vascular systems
- To communicate with the patient in order to obtain informed consent prior to diagnostic imaging and interventional procedures of the cardiac, vascular and lymphatic systems
- To choose optimal imaging protocols for radiographic, ultrasonographic, CT and MRI examinations of the cardiac and vascular systems
- To create and apply protocols and standard operating procedures to reduce exposure doses for radiological examinations of the cardiac and vascular systems
- To confidently supervise and teach technical staff to ensure that appropriate images are obtained for all radiological methods pertaining to cardiac and vascular imaging
- To confidently judge the quality of the imaging examinations in cardiac imaging and to devise strategies to improve image quality
- To confidently interpret and report cardiac and vascular CT for common clinical indications
- To interpret and report cardiac and vascular CT under supervision for rare clinical indications

- To confidently interpret and report cardiac and vascular MR for common clinical indications
- To interpret and report cardiac and vascular MRI under supervision for rare clinical indications
- To confidently report radiographic examinations of the cardiac and vascular systems for common and rare diseases
- To use imaging findings for clinical decision-making
- To appreciate own limitations and to identify when it is appropriate to obtain assistance in interpreting and reporting images of the cardiac and vascular systems
- To confidently identify urgent and/or unexpected findings in imaging examinations of the cardiac and vascular systems and to communicate these timely and properly
- To communicate with patients and their relatives in order to explain their imaging findings of the cardiac and vascular systems
- To communicate with referring clinicians to discuss radiological findings of the cardiac and vascular systems
- To perform at multidisciplinary conferences and tumour boards for diseases of the cardiac and vascular systems

B-II-3 CHEST RADIOLOGY

Content reviewed by ESTI (European Society of Thoracic Radiology)

INTRODUCTION

In Level II the trainee should, in addition to the knowledge, competencies and skills acquired in the first 3 years of training, have in-depth knowledge of the following:

- Normal anatomy and common variants of the chest, including lungs, heart, mediastinum, pleura, main vessels, thoracic wall and skeletal structures
- The pathology and radiological presentation of parenchymal, mediastinal and pleural diseases and the standard treatments available
- The radiological presentation of pathologies of the main vessels, thoracic wall and skeletal structures and the treatments available
- The understanding of imaging features of traumatic chest injury
- Staging of lung cancer and the role of imaging
- An understanding of the expected changes after surgery, radiotherapy and interventional procedures

Trainees should be able to perform, interpret and report on chest radiographs, ultrasound, CT and chest MRI for common clinical indications as well as rare clinical indications (under supervision).

Trainees should be able to confidently justify diagnostic imaging examinations and/or interventional procedures of the chest and choose the best-suited imaging method to achieve the best diagnosis while applying techniques to reduce exposure doses when applicable and possible.

KNOWLEDGE

NORMAL ANATOMY

- To describe the anatomy of the lobar and segmental bronchi
- To describe the topographic relationships of the hilar vessels and bronchi
- To describe the pulmonary lobule and its component parts
- To know the terminology for describing the site and size (adenopathy, enlarged lymph node, normal lymph node) of mediastinal and hilar lymph nodes
- To describe the anatomy and normal variants of aortic arch branching, including the common origin of the brachiocephalic and left common carotid arteries (“bovine arch”)
- To confidently identify the following structures on chest CT:
 - » Pulmonary lobes and segments
 - » A pulmonary lobule and associated structures
 - » Fissures – major, minor, azygos and common accessory fissures

- » Extrapleural fat
- » Inferior pulmonary ligaments
- » Airway – trachea, carina, main bronchi, lobar bronchi and segmental bronchi
- » Heart – left and right ventricles, left and right atria, atrial appendages
- » Pericardium – including superior pericardial recesses
- » Pulmonary arteries – main, right, left, interlobar, segmental
- » Aorta – sinus of Valsalva, ascending, arch and descending aorta
- » Arteries – brachiocephalic (innominate), common carotid, subclavian, axillary, vertebral, internal mammary arteries, bronchial arteries, coronary arteries
- » Veins – pulmonary, superior vena cava, inferior vena cava, brachiocephalic, subclavian, internal jugular, external jugular, azygos, hemi-azygos, left superior intercostal, internal mammary
- » Oesophagus
- » Thymus
- » Normal mediastinal and hilar lymph nodes
- » Azygo-oesophageal recess
- » Soft and osseous structures of the chest wall

ALVEOLAR LUNG DISEASES AND ATELECTASIS

- To list the most common causes of adult (acute) respiratory distress syndrome
- To list predisposing causes of or associations with organising pneumonia
- To describe the most common causes of bronchiectasis
- To describe the imaging features and basic clinical features of centrilobular, paraseptal and panacinar emphysema
- To describe the imaging findings used to identify surgical candidates for giant bullectomy or lung volume reduction interventions
- To describe the imaging patterns of segmental and lobar consolidation and to list common causes
- To describe the imaging features of partial or complete atelectasis of single or combined lobes on chest radiographs and to list likely causes
- To describe the imaging features of complete unilateral lung collapse on a chest radiograph and to list the appropriate causes of the collapse
- To distinguish lung collapse from massive pleural effusion on a frontal chest radiograph
- To recognise the halo sign and its association with a diagnosis of invasive aspergillosis in an immunosuppressed patient
- To describe the imaging features of bronchiectasis on chest radiographs and chest CT
- To describe the high-resolution CT (HRCT) signs of small airways disease and to differentiate between the direct signs (tree-in-bud, centrilobar changes) of exudative bronchiolitis and the indirect signs (mosaic pattern, air-trapping) of obliterative bronchiolitis (bronchiolitis obliterans)
- To describe the typical imaging patterns and basic clinical features of cystic fibrosis
- To describe the typical imaging patterns of tracheal and bronchial stenoses and to list the most common causes
- To describe the typical imaging patterns and basic clinical features of centrilobular emphysema on chest radiographs and CT
- To recognise a unilateral hyperlucent lung on chest radiographs and to list an appropriate differential diagnosis
- To recognise the effects of various pathological processes on the component parts of the pulmonary lobule, as seen on HRCT
- To describe the pathophysiology of the following imaging patterns:
 - » Ground glass opacity and lung consolidation
 - » Linear and reticular pattern

- » Nodular pattern
- » Honeycombing pattern
- » Mosaic attenuation pattern
- » Air-trapping
- » Cysts and cyst-like structures
- » Centrilobular opacities and tree-in-bud
- » Crazy-paving pattern
- To describe the typical imaging features of thickening of the interlobular septa and the possible causes

SOLITARY AND MULTIPLE PULMONARY NODULES

- To describe the definitions of a solitary pulmonary nodule and a pulmonary mass
- To list the most common causes of a solitary pulmonary nodule, cavitary pulmonary nodules and multiple pulmonary nodules
- To describe the strategy for managing a solitary incidental or screen-detected pulmonary nodule detected
- To have an in-depth understanding of the roles of contrast-enhanced CT and integrated PET/CT in the evaluation of a solitary pulmonary nodule
- To understand the morphological features that indicate likelihood of benignity/malignancy a solitary pulmonary nodule and their limitations
- To describe the complications of transthoracic lung biopsy and their frequency
- To describe the indications for chest tube placement as a treatment for pneumothorax related to transthoracic lung biopsy

BENIGN AND MALIGNANT NEOPLASMS OF THE LUNG

- To list the four major histological types of bronchogenic carcinoma, and the difference in treatment between non-small-cell and small-cell lung cancer
- To describe the current TNM classification for staging non-small-cell lung cancer, including the components of each stage
- To identify abnormal contralateral mediastinal shift on a post-pneumonectomy chest radiograph and to list two possible aetiologies for the abnormal shift
- To describe the acute and chronic radiographic and CT appearance of radiation injury in the thorax (lung, pleura, pericardium) and to identify the temporal relationship with radiation therapy
- To have an in-depth understanding of the roles of CT and MRI in lung cancer staging
- To describe the role of 18F-FDG-PET and integrated PET/CT in lung cancer staging
- To describe the manifestations and the role of imaging in thoracic lymphoma
- To list the most common intra- and extrathoracic metastatic sites for non-small-cell and small cell lung cancer

THORACIC DISEASE IN IMMUNOCOMPETENT, IMMUNOCOMPROMISED AND POST-TRANSPLANT PATIENTS

- To describe the radiological manifestations of pulmonary mycobacterial infections on radiographs/CT
- To list the various types of pulmonary aspergillosis, to understand that they form part of a continuum and to recognise these entities on chest radiographs/CT
- To describe the major categories of disease-causing chest radiography/CT-abnormalities in the immunocompromised patient

- To list two typical infections and two typical neoplasms in patients with AIDS and to describe the imaging features on chest radiography and chest CT
- To describe the typical imaging features and basic clinical features of Pneumocystis jiroveci pneumonia
- To list the three most important aetiologies of hilar and mediastinal adenopathy in patients with AIDS
- To describe the relevant differential diagnoses for widespread consolidation in an immunocompromised host
- To describe the typical imaging features and basic clinical features of post-transplant lymphoproliferative disorders
- To describe the typical imaging features and basic clinical features of graft-versus-host disease

CONGENITAL LUNG DISEASE

- To describe the common types of partial anomalous venous return
- To describe the typical imaging features and basic clinical features of bronchopulmonary sequestration, congenital pulmonary airway malformations, congenital lobar overinflation and bronchogenic cyst
- To describe the typical imaging features and basic clinical features of bronchial atresia on a chest radiograph and CT, and to list the most common lobes of the lungs in which it occurs

PULMONARY VASCULAR DISEASE

- To list the most common causes of pulmonary artery hypertension and to describe the typical signs on chest radiography and chest CT
- To understand the role of CT pulmonary angiography (CTPA), MRI/MRA and lower extremity venous studies in the evaluation of a patient with suspected venous thromboembolic disease, including the advantages and limitations of each test
- To describe the typical imaging features of enlarged pulmonary arteries on a chest radiograph and to distinguish them from enlarged hilar lymph nodes
- To describe the typical imaging features and basic clinical features of acute and chronic lobar and segmental pulmonary emboli on CT angiography
- To describe the typical imaging features of vascular redistribution seen in raised pulmonary venous pressure

AIRWAYS AND OBSTRUCTIVE LUNG DISEASE

- To describe the typical imaging features and basic clinical features of bronchiectasis
- To list the typical imaging features of air-trapping
- To describe basic clinical features and typical imaging features of emphysema, including the various patterns (centrilobular, bullous and paraseptal emphysema)
- To describe the typical imaging of tracheal abnormalities, including tracheomalacia, tracheal stenosis, tracheobronchomegaly, most common tracheal tumors

INTERSTITIAL LUNG DISEASE

- To describe the imaging patterns of interstitial lung disease on chest radiographs according to whether the pattern is predominantly in the upper, mid or lower zone; or shows central or peripheral predominance
- To describe typical imaging patterns of interstitial lung disease on chest radiographs including lung consolidation, ground glass opacities, nodular patterns, reticular patterns, cystic patterns and widespread septal lines

- To describe typical imaging patterns of interstitial lung disease on HRCT according to whether the pattern is predominantly in the upper, mid or lower zone; or shows perihilar or subpleural predominance; or shows a vascular or perivascular airway, a lymphatic or perilymphatic or an interstitial distribution
- To describe typical imaging patterns of interstitial lung disease on HRCT according to whether the pattern is fibrotic or non-fibrotic, predominantly septal thickening / nodularity, ground glass opacity, reticular pattern, honeycombing, nodular pattern, air space consolidation, tree-in-bud pattern, “crazy-paving” pattern, cyst and cyst-like pattern
- To know the main CT presentations of the most frequent interstitial lung disease (ILD; sarcoidosis, usual interstitial pneumonia, non-specific interstitial pneumonia, hypersensitivity pneumonitis)

PLEURA AND DIAPHRAGM

- To describe the typical appearance of pleural effusion on ultrasound, chest radiographs and CT
- To describe the typical imaging features of pneumothorax on upright and supine chest radiographs
- To describe the typical imaging features and basic clinical features of malignant mesothelioma
- To describe the imaging features related to heart failure including pleural effusions, vascular redistribution on erect chest radiographs, interstitial and alveolar oedema
- To define the terms “asbestos-related pleural disease” and “asbestosis”, and to describe the respective imaging findings
- To describe the imaging features and basic clinical features of progressive massive fibrosis and conglomerate masses secondary to silicosis and coal worker’s pneumoconiosis
- To describe the imaging features of various forms of pleural calcification on a chest radiograph or chest CT and its association with asbestos exposure, old TB, old empyema or old haemothorax
- To describe the imaging features of diffuse pleural thickening and to list four causes
- To describe the imaging features of split pleura sign in empyema

MEDIASTINAL AND HILAR DISEASE

- To list the most common causes of an anterior/prevascular compartment mediastinal mass and to confidently identify a mass in the anterior mediastinum on chest radiographs, CT and MRI
- To list the three most common causes of a middle /visceral compartment mediastinal mass and to confidently identify a mass in the middle mediastinum on chest radiographs, CT and MRI
- To list the most common causes of a posterior /paravertebral compartment mediastinal mass and to confidently identify a mass in the posterior mediastinum on chest radiographs, CT and MRI
- To list and describe the most common causes of bilateral hilar lymph node enlargement
- To list and describe the most common causes of “egg-shell” calcified lymph nodes in the chest
- To list and describe the most common causes of a mass arising in the thymus
- To describe the typical imaging features, basic clinical features and common associations of thymoma
- To list and describe the three types of malignant germ cell tumour of the mediastinum
- To describe the mechanisms and signs of pneumomediastinum
- To describe the imaging appearances of normal vessels or vascular abnormalities that may mimic a solid mass
- To describe the imaging features of mediastinal and hilar lymphadenopathy on chest radiographs, chest CT and chest MRI
- To describe the imaging signs of a benign cystic teratoma
- To describe the imaging signs of an intrathoracic thyroid mass

- To describe the imaging features of cystic mediastinal masses and to describe the differential diagnoses of a bronchogenic pericardial, thymic or oesophageal duplication cyst

THORACIC AORTA AND THE GREAT VESSELS

- To describe the significance of a right aortic arch with mirror image branching versus an aberrant subclavian artery
- To have an in-depth understanding of the advantages and disadvantages of CT, MRI/MRA and trans-oesophageal echocardiography in the evaluation of the thoracic aorta
- To define the terms “aneurysm” and “pseudoaneurysm” of the aorta
- To describe the imaging features and basic clinical features and to distinguish each of the following on chest CT and MRI: aortic aneurysm, aortic dissection, aortic intramural haematoma, penetrating atherosclerotic ulcer, ulcerated plaque, ruptured aortic aneurysm, sinus of Valsalva aneurysm, subclavian or brachiocephalic artery aneurysm, aortic coarctation, aortic pseudocoarctation and cervical aortic arch
- To describe the imaging features of the two standard types of right aortic arch and double aortic arch on chest radiographs, CT and MRI
- To describe the imaging features of an aberrant subclavian artery on chest CT
- To describe the imaging features seen in arteritis of the aorta on chest CT and MRI

CHEST TRAUMA

- To list three common causes of abnormal lung opacity following trauma on chest radiographs or CT
- To list the three most common causes of post-traumatic pneumomediastinum
- To describe the imaging features of a posttraumatic widened mediastinum on chest radiographs and to list the possible causes (including aortic / arterial injury, venous injury, fracture of sternum or spine)
- To describe the indirect and direct signs of aortic injury on contrast-enhanced chest CT
- To describe the imaging features and basic clinical features and to understand the significance of chronic traumatic pseudoaneurysm on chest radiographs, CT and MRI
- To describe the imaging features of fractured ribs, clavicle, spine and scapula on chest radiographs or CT
- To describe the imaging features of an abnormally positioned diaphragm or loss of definition of a diaphragm on chest radiographs following trauma and the association with a ruptured diaphragm
- To describe the imaging features of a pneumothorax and pneumomediastinum following trauma on chest radiographs
- To describe the imaging features of a cavitary lesion following trauma on chest radiographs or chest CT and to describe the association with laceration and pneumatocele formation, haematoma or abscess secondary to aspiration
- To describe the imaging features and to distinguish between pulmonary contusion, laceration and aspiration

POSTOPERATIVE CHEST

- To identify normal postoperative findings and complications of the following procedures on chest radiographs, chest CT and chest MRI:
 - » Wedge resection mastectomy, lobectomy
 - » Pneumonectomy
 - » Coronary artery bypass graft surgery
 - » Cardiac valve replacement
 - » Aortic graft
 - » Aortic stent

- » Transhiatal oesophagectomy
- » Lung transplant
- » Heart transplant
- » Lung volume reduction surgery

SKILLS

- To prepare a patient for chest CT including indication, venous access and heart-rate control
- To choose optimal acquisition parameters for chest CT
- To choose optimal post-processing tools for chest CT
- To manage procedural complications in the diagnosis and treatment of chest disease
- To design and optimise CT protocols and to adapt these protocols to evaluate each of the following:
 - » Thoracic aorta and great vessels
 - » Superior vena cava and brachiocephalic vein stenosis or obstruction
 - » Pulmonary embolism
 - » Diffuse lung disease
 - » Tracheobronchial tree
 - » Bronchiectasis
 - » Small airway disease
 - » Lung cancer staging
 - » Oesophageal cancer staging
 - » Superior sulcus tumour
 - » Pulmonary metastases
 - » Pulmonary nodule on a radiograph
 - » Shortness of breath
 - » Haemoptysis
 - » Chest pain
- To confidently perform a radiological staging of lung cancer
- To perform the following imaging-guided transthoracic interventions under appropriate supervision, to understand the indications and contraindications, and to manage the complications:
 - » Paracentesis and drainage of pleural effusions
 - » Transthoracic lung biopsy
 - » Paracentesis of mediastinal and pericardial fluid collections
 - » Drainage of refractory lung abscess
- To apply inspiratory and expiratory imaging depending on the clinical indication
- To independently perform post-processing tasks for chest imaging studies, including multiplanar reformations (MPR), maximum intensity projections (MIP), minimum intensity projections (MinIP), volume rendering tools (VRT) and vessel analysis tools

COMPETENCES AND ATTITUDES

- To confidently justify diagnostic imaging examinations (including CT and MRI) and/or interventional procedures of the chest
- To confidently choose the best-suited method for evaluating chest disorders
- To obtain informed consent of the patient prior to interventional procedures of the chest and/or diagnostic examinations
- To choose optimal imaging protocols for radiographic, ultrasonographic, CT and MRI examinations of the chest
- To create and apply protocols and standard operating procedures to reduce exposure doses for radiological examinations of the chest

- To confidently supervise and teach technical staff to ensure that appropriate images are obtained for all radiological methods pertaining to chest imaging
- To confidently judge the quality of thoracic imaging examinations and to devise strategies for image quality improvement
- To confidently interpret and report chest CT for common clinical indications
- To interpret and report chest CT under supervision for rare clinical indications
- To make a specific diagnosis of interstitial lung disease (ILD) when HRCT appearances are characteristic
- To confidently interpret and report chest MRI for common clinical indications
- To interpret and report chest MRI under supervision for rare clinical indications
- To confidently report radiographic examinations of the chest for common and rare diseases
- To appreciate own limitations and to identify when it is appropriate to obtain assistance in interpreting and reporting thoracic imaging studies
- To confidently identify urgent and/or unexpected findings in imaging examinations of the chest and to communicate these timely and properly
- To communicate with patients and their relatives in order to explain imaging findings on their chest imaging study
- To communicate with referring clinicians to discuss radiological findings of the chest
- To perform at multidisciplinary conferences and tumour boards for chest diseases

B-II-4 EMERGENCY RADIOLOGY

Content reviewed by ESER (European Society of Emergency Radiology)

INTRODUCTION

In Level II the trainee should, in addition to the knowledge, competencies and skills acquired in the first 3 years of training, have in-depth knowledge of the following:

- Normal anatomy and common variants of the relevant body systems for more independent functioning, as well as that knowledge can be taught to junior trainees in years 1-3
- To know the radiological modalities and techniques employed in Emergency Radiology (ER) regarding guidelines and corresponding institutional Standard Operation/imaging algorithms for polytrauma cases, standard procedures in emergency and ER factors and effects of radiation dose as well as techniques for dose reduction and their consecutive image quality
- To understand the principles and basic application such as the Injury Severity Score (ISS) for trauma cases, the pain rating scales in non-traumatic emergencies, legal issues and hygiene regulations
- To know the potential risks and benefits of modality dependent contrast media including effects of oral, rectal or bladder filling
- To describe the radiological standard procedures in CT under resuscitation and mass casualty incidents, indications and contraindications for image-guided interventional procedures in emergency settings
- To have a basic understanding of the workflow chain of digital imaging, image processing, reading, reporting and the distributing report / images in ER

KNOWLEDGE

ANATOMY

- To describe and have an in-depth understanding of relevant normal anatomy of the brain, spine, musculoskeletal system, lung, heart, mediastinum, diaphragm, abdominal organs and spaces, genito-urinary tract, venous and arterial system including topographic relationships and cross-sectional appearance
- To describe and have an in-depth understanding of common and uncommon normal variants and distinction from acute pathology

CENTRAL NERVOUS SYSTEM AND BRAIN

- The trainee is required to be able to describe the imaging features and basic clinical findings of:
 - » skull fractures
 - » intracranial haemorrhages (subdural, epidural, subarachnoidal, parenchymal)
 - » parenchymal injuries (cortical contusion, diffuse axonal injury, deep gray matter injury, brainstem injury)
 - » extra- and intracranial vascular injuries

- » penetrating injuries
- » increased intracranial pressure and herniation syndromes
- » arterial cerebral infarction (including the description of particular technical issues such as MR-DWI, MR-perfusion, MRA, CE-MR, TOF, CT-perfusion, CTA)
- » central nervous system infections (meningitis, encephalitis, abscess / cerebritis, subdural empyema, intracranial and spinal epidural abscess, osteomyelitis / discitis)
- » acute cord compression
- » dural sinus thrombosis

FACE AND SKULL

- The trainee is required to be able to describe the imaging features and basic clinical findings of:
 - » facial fractures (orbital blow-in and blow-out fractures, nasal fractures, naso-orbital-ethmoid fractures, frontal fractures, maxillary fractures, dentoalveolar fractures, Le-Fort fractures, mandible fractures)
 - » orbital injuries (post bulbar emphysema and haemorrhage)
 - » ocular injuries (rupture, laceration, lens dislocation, vitreous haemorrhage, subchoroidal haemorrhage)
 - » trauma to the larynx, pharynx and upper oesophagus
 - » orbital, epidural, subdural or other abscesses / empyema
 - » infections of the paranasal sinuses (acute, fungal, chronic sinusitis, complications)
 - » infections of the suprahyoid neck (retropharyngeal and paravertebral abscess, tonsillitis and peritonsillar abscess, odontogenic infections, submandibular and sublingual abscess, parotitis, sialoadenitis, cervical necrotising fasciitis)
 - » acute infections of the infrahyoid neck (epiglottitis, lymphadenitis, jugular thrombophlebitis)
 - » external and internal ear infection and mastoiditis (cholesteatoma, apical petrositis)
 - » orbital infections and optic neuritis

SPINE

- To describe the evaluation criteria of low-risk and high-risk patients and of patients with neurological deficits (such as prediction rules, Nexus, CCR)
- To describe the imaging features and basic clinical features of spinal/plexus trauma (spinal cord contusion, spinal epidural hematoma, nerve root avulsion, plexus injuries)
- To describe the assessment of instability of fractures
- To describe and have an in-depth understanding of different mechanisms of injury such as hyperextension / hyperflexion, compression, burst, distraction, translation-rotation injury including the description of frequently associated injuries
- To describe the imaging features and basic clinical features of different vertebral injuries (occipital condyle fracture, Jefferson burst fracture, atlanto-axial rotary fixation, Hangman's fracture, whiplash injury, wedge compression, burst compression, flexion tear drop fracture, bilateral facet dislocation, chance fracture, complex fracture, pathological fracture, injuries to intervertebral disks)
- To describe the imaging features and basic clinical features of spinal cord injury
- To describe the imaging features and basic clinical features of disc herniation
- To describe the imaging features, basic clinical features and common causing pathogens of infections (osteomyelitis, discitis, spondylodiscitis, epidural abscess)

CHEST, CARDIO-VASCULAR

- The trainee is required to be able to describe the imaging features and basic clinical findings of:
 - » chest trauma (rib fractures, sternal fractures, hemothorax, pneumothorax, pneumomediastinum, pulmonary contusion/ laceration/ hematoma, pneumatocele, tracheal and bronchial injury, oesophageal injury, diaphragm injury)
 - » acute pulmonary infections including the various etiologies and causing pathogens as well as aspiration pneumonia
 - » airway foreign bodies
 - » severe obstructive airway disease
 - » ARDS
 - » cardiac emergencies (myocardial infarction, myocardial laceration or contusion, pericardial effusion or tamponade, pericardial laceration, pneumopericardium, cardiac valve injury, endo- and myocarditis)
 - » aortic emergencies (thoracic aortic trauma, supra-aortic injuries including carotid and vertebral injuries, aortic dissection, aortic aneurysms, aortitis)
 - » pulmonary oedema including the various etiologies
 - » thromboembolic disease including the fat embolism syndrome
- To describe and have an understanding of combination protocols in CT for concurrent ruling out of multiple life-threatening causes of chest pain

ABDOMEN

- The trainee is required to be able to describe the imaging features and basic clinical findings of:
 - » hemoperitoneum and intraperitoneal fluids
 - » retroperitoneal haemorrhage
 - » intraperitoneal and retroperitoneal gas collections
 - » active arterial extravasation
 - » organ injuries (liver, spleen, adrenal, kidney, pancreas, gallbladder, bowel, mesentery, bladder)
 - » abdominal wall injuries
 - » aortic and major vessel trauma
 - » emergencies related with the peritoneal cavity (peritonitis, abdominal abscess, insufficient bowel anastomosis, hollow organ perforation, ascites)
 - » liver and biliary tract including obstructive and non-obstructive jaundice and cholecystitis
 - » pancreatitis
 - » the urinary tract (urinary stones, infection, pyelonephritis, renal abscess, renal infarction)
 - » adrenal haemorrhage
 - » non-traumatic emergencies of the gastrointestinal tract (gastrointestinal haemorrhage, bowel obstruction, bowel perforation, bowel infarction, omental infarction, appendicitis, diverticulitis, infectious enteritis and colitis, epiploic appendagitis, inflammatory bowel disease, Crohn's disease, ulcerative colitis, abdominal compartment syndromes and hernia complications)

GYNECOLOGY / OBSTETRICS

- The trainee is required to be able to describe the imaging features and basic clinical findings of:
 - » foeto-placental trauma
 - » ovarian torsion
 - » pelvic inflammatory disease and abscesses
 - » acute abdominal disease in pregnancy
 - » major and minor trauma in pregnancy
 - » ectopic pregnancy

MALE GENITOURINARY

- The trainee is required to be able to describe the imaging features and basic clinical findings of:
 - » urethral and penile trauma
 - » urethral stones and foreign bodies
 - » scrotal and testicular trauma
 - » testicular torsion of the epididymal appendix
 - » epididymitis and orchitis
 - » testicular infarction of scrotal abscess
 - » Fournier gangrene

PELVIS

- The trainee is required to be able to describe the imaging features and basic clinical findings of:
 - » pelvic ring fractures and disruptions
 - » isolated fractures without pelvic ring involvement
 - » bladder injury
- Furthermore, the trainee is able to describe the supportive interventional procedures in bleeding control

EXTREMITIES (INCLUDING SHOULDER AND HIP)

- The trainee is required to be able to describe the imaging features and basic clinical findings of:
 - » fractures including stress and insufficiency fractures and their classification
 - » luxations and their classification
 - » chondral and osteochondral lesions and their classification
 - » ligament tears or ruptures and their classification
 - » meniscal and labral tears and their classification
 - » tendon and muscular injuries and their classification
 - » acute inflammatory diseases
 - » avascular necrosis
 - » acute compartment syndromes

PAEDIATRIC, INTERVENTIONAL, MUSCULOSKELETAL AND OTHERS

- As long as not mentioned so far: To describe the imaging features and basic clinical features as provided in the corresponding emergency sections of the respective subspecialty curricula
- As long as not mentioned so far: To describe the interventional procedures as provided in the corresponding emergency sections of the respective subspecialty curricula

SKILLS

- To use and optimise efficiency enhancing technical equipment for initial interpretation of CT studies (e.g., dedicated CT workstation)
- To independently perform the following, while acknowledging own limitations and indication to call in expertise of supervisor:
 - » e-FAST
 - » abdominal sonography and contrast-enhanced sonography of emergency cases
 - » femoral artery and venous puncture techniques
- To perform under supervision:
 - » image guided drainage of fluid collections
 - » percutaneous cholecystectomy and nephrostomy
 - » other interventional emergency procedures under image guidance, particularly in bleeding control
- To confidently identify modality dependent imaging findings of misplacement of devices such as tubes, drains and catheters
- To confidently identify modality-and body-region-dependent common imaging findings in emergency cases such as fracture patterns, ileus, large and small bowel obstruction, free air and fluid, bleeding, infarction, organ injury
- To confidently classify modality-dependent imaging findings as acute life-threatening, major but not immediately life-threatening, severe but not life-threatening or self-limiting acute conditions
- To confidently classify modality-dependent imaging findings according to curricular content provided by other subspecialties
- To perform image interpretation or therapy of >1500 emergency cases (>500 CR, >100 eFAST, >200 US, >500 CT including >25 polytrauma cases and cardiovascular emergencies cases, >50 MRI, >10 embolisations, >10 percutaneous transhepatic drainage (PTD), >30 drainage of fluid collections). These cases have to be distributed proportionally over the body regions and typical pathologies
- To interpret, report, communicate and demonstrate common and typical findings
- To interpret, report, communicate and demonstrate rare findings under supervision
- To supervise the imaging quality of emergency CT, radiographic and MRI examinations including image postprocessing
- To manage procedural complications of imaging in the emergency setting

COMPETENCES AND ATTITUDES

- To confidently differentiate high-risk from low-risk patients before imaging
- To confidently differentiate and prioritise findings with respect to their urgency after imaging
- To confidently 'screen' as fast as possible for life-threatening findings (e.g., for CT: <10 min after scan start) using an optimised infrastructure and selective image reading in case of high-risk patients
- To have an in-depth understanding of the respective advantages and disadvantages of different imaging options in emergency cases
- To be able to choose and to justify the best-suited imaging modality and protocol parameters and, if necessary, to put imaging techniques into the most appropriate diagnostic pathway considering advantages and limitations of the different modalities, diagnostic accuracy and speed, amount of radiation exposure and ethically motivated individual risk / benefit-analysis with respect to case severity, time-to-diagnose / therapy, patient age and sex including pregnant patients
- To be integral and active part of continuous workflow optimisation with particular respect to ethical considerations, improvement of diagnostic accuracy and shortening of the time-to-diagnose / therapy
- To chair at multidisciplinary treatment, morbidity and mortality conferences
- To supervise, teach and train technical staff to ensure with respect to appropriate emergency workflow and imaging
- To communicate timely and properly with patients (if possible), their relatives (if needed) and the other medical disciplines involved in order to explain imaging findings of disorders and to rapidly evaluate adequate therapy with respect to best possible outcome
- To participate in Quality Assessment and Quality Monitoring
- To appreciate own limitations and to respect the roles and responsibilities of other members of the multidisciplinary emergency team, being an integral part of the team in decision-making

B-II-5

GASTROINTESTINAL AND ABDOMINAL RADIOLOGY

Content reviewed by ESGAR (European Society of Gastrointestinal and Abdominal Radiology)

INTRODUCTION

In Level II the trainee should, in addition to the knowledge, competencies and skills acquired in the first 3 years of training, have in-depth knowledge of the following:

- Organ-based approach to diseases and comprehensive outline of the techniques and skills that are necessary for patient management, which includes:
 - » Imaging modalities, application and modification of imaging protocols according to specific clinical indications
 - » Expected changes after surgery, radiation and interventional procedures
- Imaging manifestations of benign and malignant diseases and interpretation of signs on imaging that indicate the severity of disease and how this influences management
- Practical skills to perform specialist diagnostic imaging examinations and interventional procedures

KNOWLEDGE

IMAGING TECHNIQUES – GENERAL REQUIREMENTS

- To describe the indications and contraindications for the various imaging examinations in abdominal imaging
- To describe the relative costs of the various imaging examinations in abdominal imaging
- To describe the indications and contraindications for enema techniques and the optimal contrast material and technique to be used in each clinical situation
- To list the indications for a contrast-enhanced ultrasound study of the liver
- To describe the techniques for quantification of diffuse parenchymal diseases using ultrasound, CT and MRI, and their clinical role and limitations in abdominal imaging
- To list the strengths and limitations of endosonography in abdominal imaging
- To describe the techniques for CT colonography, CT/MR enterography and CT/MR enteroclysis
- To describe the techniques and role for post-processing images including endoluminal reconstructions, fusion images and post-processing of functional studies in abdominal imaging
- To describe the technique of FDG PET/CT, the development of new tracers, and sensitivity and specificity of PET/CT in most common abdominal tumours, including liver metastases of extra-abdominal origin
- To understand the principles and limitations of single and double contrast studies of the gastrointestinal tract and to appreciate their advantages and disadvantages compared with endoscopy

- To describe the main indications, contraindications and basic technique for ablation of liver tumours using ultrasound and/or CT guidance
- To describe the main indications and techniques of liver biopsy
- To describe the basic principles of balloon angioplasty and stenting of abdominal visceral arteries for the treatment of stenosis and aneurysms
- To describe the rationale, technique, principle and results of therapeutic embolisation and transarterial chemoembolisation in the abdomen

ANATOMY AND PHYSIOLOGY

- To understand the indication and techniques for interventional procedures within the abdomen, including hepatobiliary intervention and luminal stenting
- To describe normal post-therapeutic imaging related to previous surgery, intervention or radiation therapy in the abdomen

OESOPHAGUS

- To describe the imaging features of oesophageal cancer, diverticulum, extrinsic compression, submucosal masses, fistulae, hiatus hernia, oesophageal varices, benign strictures, benign tumours, varices and oesophagitis on examinations of the oesophagus
- To understand the significance of Barrett's oesophagus and the clinical manifestations of this disease
- To describe the appearance of common motility disorders of the oesophagus on barium studies and cross-sectional imaging
- To understand the role of PET or PET/CT in the staging of oesophageal cancer
- To have a basic understanding of the surgical techniques in oesophageal surgery and post-surgical appearances on imaging examinations
- To describe the imaging features of oesophageal cancer on CT and to describe the criteria for lymph node involvement and non-resectability
- To understand the use of endoscopic ultrasound in the staging of oesophageal cancer and the technique of endoscopic ultrasound-guided biopsy

STOMACH AND DUODENUM

- To describe the most appropriate imaging examination and contrast medium use in suspected perforation of the stomach or duodenum and in postoperative follow-up and to list the limitations of each examination for these specific situations
- To understand the role of endoscopic ultrasound and PET or PET/CT in the staging of gastric cancer
- To describe a CT protocol tailored for gastric cancer staging
- To have a basic understanding of bariatric surgery procedures, the normal radiological postoperative appearance and signs of common complications

- To have a basic understanding of the imaging features of a variety of conditions of the stomach and duodenum such as benign and malignant tumours, infiltrative disorders, e.g., linitis plastica, gastric ulcers and positional abnormalities, including hiatus hernia and gastric volvulus
- To describe the imaging features of duplication cysts of the upper gastrointestinal tract on CT
- To describe rotational abnormalities of the duodenum and the appearance of annular pancreas, submucosal tumours, papillary tumours and inflammatory disease including peptic ulceration

SMALL BOWEL

- To describe the most appropriate imaging examination for small bowel obstruction, inflammatory disease, infiltrative disease, small bowel perforation and ischaemia, cancer, lymphoma, carcinoid tumour and postoperative follow-up; and to list the limitations of each examination for these clinical scenarios
- To describe the MRI and CT techniques of enterography and enteroclysis
- To describe the indications for capsule endoscopy and to list the limitations and potential complications of the examination
- To describe the typical imaging features of the following disorders: adenocarcinoma, polyposis, stromal tumour, lymphoma, carcinoid tumour, Crohn's disease, adhesion, haematoma, internal hernia, malrotation, lymphoid hyperplasia, Whipple's disease, amyloidosis, radiation-induced injury, malrotation, Meckel's diverticulum, coeliac disease, diverticulosis, fistula and systemic sclerosis
- To understand the principles of the interpretation of CT examination of the small bowel
- To describe the interpretation of MRI of the small bowel, especially in cases of inflammatory bowel disease

COLON AND RECTUM

- To describe the optimal imaging examination and outline the technique for study of the colon according to the suspected disease (obstruction, volvulus, diverticulitis, benign tumour, inflammatory disease, cancer, lymphoma, uncommon lesions of the colon and rectum, perforation, postoperative evaluation) and to list the limitations of each technique
- To understand the imaging features of inflammatory bowel disease and the technique and the value of MRI, ultrasound and CT for initial assessment and follow-up
- To understand the current indications for CT colonography, including its potential role in colorectal cancer screening
- To describe the TNM classification of colon cancer and its prognostic value, the technique and the value of MDCT, MRI and endosonography, in the staging of rectal cancer
- To describe the CT imaging features of colon cancer and the signs that assess local tumour staging or indicate metastasis
- To describe the most common diseases of the rectum and the anus and the most frequent operative techniques that may be used to treat them
- To describe the MRI techniques for imaging of rectal cancer and anorectal squamous carcinoma
- To describe the staging of rectal adenocarcinoma according to the TNM stage, extramural vascular invasion, relation to the mesorectal fascia, peritoneum and anal sphincter and to describe the potential limitations of MRI
- To describe imaging patterns and modalities used to assess locally recurrent or metastatic colorectal cancer
- To describe the staging of anorectal squamous cell carcinoma and understand the key differences compared to rectal cancer staging
- To understand the role of PET/CT in staging anorectal squamous cell cancer

- To describe imaging features that may differentiate between complete response with posttreatment fibrosis and residual tumour or tumour regrowth or recurrence after oncological treatment for anorectal malignancies
- To describe the appearances and differential diagnosis of retrorectal cysts
- To have a basic understanding of the MRI technique that is used to search for a pelvic / perianal fistula and to describe the appearance of fistulae on MRI
- To describe the appearances of anal sphincter injury and perianal sepsis on MRI and endoanal ultrasound
- To describe the basic imaging features of functional and anatomical disorders on both fluoroscopic and MR proctography and the appearance of pelvic floor muscle tears and atrophy using MRI

PERITONEUM AND ABDOMINAL WALL

- To describe the types of abdominal wall hernias and imaging features of hernial strangulation on CT and on ultrasound
- To describe the imaging features of rectus sheath hematoma on ultrasound, CT and MRI
- To describe the imaging features of ascites on ultrasound, CT and MRI and to describe the features of loculated ascites
- To describe the imaging features of mesenteric tumour and localisation on ultrasound, CT and MRI
- To describe the imaging features of mesenteric cysts on ultrasound, CT and MRI
- To describe the imaging features and basic clinical features of the following peritoneal diseases on CT and MRI: peritonitis, peritoneal carcinomatosis, peritoneal tuberculosis, mesenteric lymphoma, mesenteric panniculitis, epiploic appendagitis and omental infarction

ABDOMINAL VESSELS

- To describe the respective roles of angiography and CT angiography in acute gastrointestinal haemorrhage and the advantages and limitations of the techniques

LIVER

- To have a detailed understanding of liver anatomy and segmentation and vessel anatomy, including variants in vascular anatomy that may affect surgical planning
- To describe the most common surgical procedures for hepatectomy and liver transplantation and their post-treatment appearance and complications
- To describe the imaging features and basic clinical features of vascular diseases of the liver, including Budd-Chiari Syndrome, hereditary haemorrhagic telangiectasia, portal vein thrombosis
- To describe the imaging features of cystic echinococcosis (hydatid cyst) on ultrasound, CT and MRI
- To differentiate between amoebic abscess and pyogenic abscess of the liver regarding appearance, evolution, treatment, and indication for drainage
- To describe the imaging features of FNH and hepatic adenoma (including subtypes) on ultrasound, Doppler, contrast-enhanced ultrasound, CT and MRI, including hepato-biliary contrast agents
- To describe the imaging features of homogeneous and heterogeneous liver steatosis (diffuse and focal) on ultrasound, CT and MRI (including imaging quantification)
- To describe the natural history of hepatocellular carcinoma (HCC), the major techniques, staging and the indications for treatment (surgical resection, chemo- or radioembolisation, percutaneous ablation, liver transplantation, systemic therapy)

- To describe the staging of HCC in order to discuss indications for treatment
- To describe the typical imaging features of benign and malignant focal liver lesions on MRI with hepato-biliary contrast agents
- To describe the imaging features of peripheral cholangiocarcinoma and to describe the staging and features that influence treatment (surgery vs. palliation)
- To describe rare tumours types affecting the liver and their radiological appearance
- To describe the imaging appearance and methods for quantification of fibrosis and liver iron overload on different imaging modalities
- To describe the technique for percutaneous image-guided liver biopsy and its most common indications
- To describe the complications of percutaneous image-guided liver biopsy and to precisely evaluate the occurrence of morbidity and mortality
- To describe current applications and limitations of different MRI-sequences for liver imaging, including diffusion-weighted imaging

BILIARY TRACT

- To know the strengths and weaknesses of different imaging methods for the detection of gall bladder and common bile duct stones
- To describe unusual features of cholecystitis like gangrenous, emphysematous and acalculous cholecystitis on ultrasound and CT
- To describe the imaging features of periductal cholangiocarcinoma (Klatskin's tumour) and to describe the tumour staging and features that influence treatment (surgery vs. palliation)
- To describe the imaging features of ampullary carcinoma on ultrasound, CT and MRI, including magnetic resonance cholangiopancreatography (MRCP) and endoscopic ultrasound
- To describe the natural history and risk of malignancy of sclerosing cholangitis and typical imaging features on ultrasound, CT and MRI, including MRCP
- To describe the main techniques for surgery of the bile duct and its common complications
- To describe the imaging features of biliary leaks on imaging examinations
- To describe the imaging features of gallbladder polyps, including assessment of malignancy risk

PANCREAS

- To describe the natural history of chronic pancreatitis and to list the common causes
- To describe the imaging features of pancreatic calcifications on ultrasound and CT
- To describe the tumour staging for pancreatic adenocarcinoma including criteria for non-resectability
- To describe the typical imaging features of cystic tumours of the pancreas, including serous cystadenoma, mucinous cystic neoplasms, intraductal papillary mucinous tumours (IPMN), the indications and modalities used for tumour characterisation and the indication for follow-up imaging for IPMN
- To describe the main techniques for pancreatic surgery and to list their potential complications
- To describe the imaging features of the different pancreatitis-related collections, and to discuss the advantages and limitations of different treatments (follow-up, interventional procedure, percutaneous or endoscopic surgery)
- To list the indications and rationale for functional examinations of the pancreas (e.g., MRCP following secretin stimulation)

SPLEEN

- To describe optimal imaging techniques depending on the clinical situation (e.g., trauma, staging of lymphoproliferative disorders, investigation of a focal lesion etc.)
- To list the causes and imaging features on different imaging modalities (including nuclear medicine) of focal splenic abnormalities, including infection, both benign and malignant masses, pseudolesions and variants, ...
- To describe the causes of splenic calcification

SKILLS

- To choose the most appropriate imaging examination according to the clinical problem in abdominal imaging
- To choose the most suitable contrast material and its optimal use according to the imaging technique and the clinical problem in abdominal imaging
- To plan an MRI examination of the upper abdomen and to adapt it to the individual clinical indication regarding to the potential use of intravenous contrast medium, intraluminal contrast medium, contrast medium phase (e.g., arterial phase or delayed imaging), magnetic resonance cholangiopancreatography (MRCP), and quantification of liver fat/iron
- To plan an MRI examination of the rectum and anal canal and to adapt it to the individual clinical indication
- To plan an MRI examination of the small bowel and to know the proper preparation
- To perform contrast medium examinations of the pharynx, oesophagus, stomach, and the bowel
- To perform video-fluoroscopy of the swallowing mechanism
- To perform contrast studies of the upper gastrointestinal tract with the most appropriate contrast material
- To perform both single and double contrast studies as well as motility assessments of the gastrointestinal tract
- To perform a single contrast enema
- To perform pouchograms and loopograms
- To confidently plan a CT examination of the abdomen and to tailor it to the individual situation in regard to intravenous contrast medium, rate of injection, dose and delay of the contrast medium and to a potential intraluminal contrast medium application, with a dose as low as reasonably achievable
- To confidently plan an MRI examination of the upper abdomen and to tailor it to the individual situation in regard to the potential use of intravenous contrast medium, rate of injection, dose and delay of the contrast medium, potential intraluminal contrast medium, magnetic resonance cholangiopancreatography (MRCP)
- To confidently plan an MRI examinations of the small bowel, rectum and anal canal and to adapt it to the individual situation, including the application of endoluminal contrast
- To apply techniques for quantification of diseases using ultrasound, CT and MRI, based on an in-depth understanding of their clinical role and limitations.
- To perform MRI and CT enterography
- To perform ultrasound examinations of the liver, gall bladder, biliary tree, pancreas and spleen
- To perform ultrasound examinations of the gastrointestinal tract and to identify the various portions (stomach, duodenum, small bowel, appendix and colon)
- To perform advanced post-processing tasks for abdominal imaging studies, including endoluminal reconstructions and fusion images in abdominal imaging
- To supervise and teach technical staff to ensure that appropriate images are obtained

Competency or experience in all of the following interventional procedures is unlikely to be achieved by many radiologists.

However, practical experience in at least 3 of the following examinations is expected:

- To perform image-guided nasogastric and nasojejunal feeding tube placement
- To assist/ and or perform image-guided percutaneous gastrostomy under supervision
- To perform percutaneous image-guided liver biopsy under supervision
- To perform image-guided biopsy of abdominal tumours with an easy access route
- To drain (image-guided) abdominal and pelvic abscesses with an easy access route
- To assist and/or perform under supervision percutaneous biliary interventions and cholecystostomy
- To assist and/or perform under supervision percutaneous biliary interventions
- To assist and/or perform under supervision radiologically guided stenting of the biliary system and gastrointestinal system, using polytetrafluoroethylene and expandable metal stents
- To assist and/or perform under supervision the ablation of liver tumours using ultrasound and/or CT guidance
- To assist and/or perform under supervision transjugular liver biopsies
- To assist and/or perform under supervision balloon angioplasty and stenting of the mesenteric arteries for the treatment of stenosis and aneurysms
- To perform under supervision transarterial chemoembolisation and simple embolisation for acute abdominal bleeding control
- To assist during radioembolisation procedures
- To assist and/or perform under supervision image-guided interventions in colon cancer, e.g., colonic stent placement in the case of colonic obstruction

COMPETENCES AND ATTITUDES

- To confidently justify diagnostic imaging examinations and/or interventional procedures of the abdomen and/or gastrointestinal system
- To confidently choose the best method for evaluating disorders of the abdomen and/or gastrointestinal system
- To communicate with the patient in order to obtain informed consent prior to diagnostic imaging and interventional procedures of the abdomen and/or gastrointestinal system
- To confidently choose optimal imaging parameters for radiographic, ultrasonographic, CT and MRI examinations of the abdomen and/or gastrointestinal system
- To confidently apply techniques to reduce exposure doses for radiographic and CT examinations of the abdomen
- To confidently design imaging protocols and standard operating procedures for CT examinations of the abdomen and gastrointestinal system, including the appropriate application of intravenous and/or intraluminal contrast, spatial and temporal resolution, and inspiration / expiration / breathhold techniques
- To confidently design imaging protocols and standard operating procedures for MRI examinations of the upper abdomen and gastrointestinal system, including the appropriate application of intravenous and/or intraluminal contrast, spatial and temporal resolution, and inspiration / expiration / breathhold techniques
- To supervise and teach technical staff to ensure that appropriate images are obtained in abdominal imaging
- To confidently judge the quality of the imaging examinations in abdominal imaging and to devise strategies to improve image quality

- To confidently report abdominal radiographs in cases of acute abdomen
- To confidently interpret and report abdominal radiographs, ultrasonographic examinations, abdominal CT studies and MRI examinations of the upper abdomen, small bowel, colon, rectum and anal canal
- To report oncological studies of the abdomen according to international standards (TNM, RECIST, WHO) applicable to the specific situation
- To appreciate own limitations and to identify when it is appropriate to obtain assistance in interpreting and reporting images of the abdomen and gastrointestinal system
- To confidently identify urgent and/or unexpected findings in imaging examinations of the abdomen and gastrointestinal system and to communicate these in a timely and proper manner
- To communicate under supervision with patients and their relatives to explain their imaging findings of the abdomen and gastrointestinal system
- To perform under supervision multidisciplinary conferences and tumour boards for diseases of the abdomen and gastrointestinal system

B-II-6

GYNAECOLOGICAL AND OBSTETRIC RADIOLOGY

Content reviewed by ESUR (European Society of Urogenital Radiology)

INTRODUCTION

In Level II the trainee should, in addition to the knowledge, competencies and skills acquired in the first 3 years of training, have in-depth knowledge of the following:

- Normal anatomy and common variants of the female reproductive organs
- The pathophysiology of diseases affecting female reproductive organs and the standard treatments available
- An understanding of the expected changes after surgery, radiation and interventional procedures
- Performing, interpreting and reporting on ultrasound, CT and MRI for common clinical indications as well as rare clinical indications (under supervision)
- Confidently justifying diagnostic imaging examinations and/or interventional procedures of the female reproductive organs and choosing the best-suited imaging method to achieve the best diagnosis while applying techniques to reduce exposure doses when applicable and possible

KNOWLEDGE

ANATOMY

- To have a detailed understanding of the normal anatomy of the female reproductive organs
- To have a detailed understanding of the physiological changes affecting normal imaging anatomy of the female reproductive organs throughout the lifespan and in relation to hormonal changes
- To have a detailed understanding of the physiological changes of the female reproductive organs during pregnancy
- To describe the dimensions of the uterus and ovaries with ultrasound
- To understand the variations of the uterus and ovaries during genital life
- To understand the variations of the uterus and ovaries during the menstrual cycle
- To list the normal pelvic compartments
- To describe the normal pelvic organs and boundaries on CT and MRI
- To describe the role of the levator ani in the physiology of the pelvic floor

CONGENITAL

- To list congenital malformations of the uterus, including uterus septatus, uterus bicornis (unicollis and bicollis) and uterus didelphys
- To describe the typical imaging features of congenital malformations of the uterus, including uterus septatus, uterus bicornis (unicollis and bicollis) and uterus didelphys

UTERUS

- To describe the indications and contraindications of transvaginal sonography and hysterosonography
- To describe the imaging features and basic clinical features of benign tumours of the myometrium
- To describe the imaging features and basic clinical features of malignant tumours of the myometrium
- To describe the imaging features and basic clinical features of tumours of the endometrium
- To describe the imaging features and basic clinical features of adenomyosis uteri
- To describe the imaging features and basic clinical features of cervical inflammation
- To describe the imaging features and basic clinical features of cervical cancer
- To describe the imaging features and basic clinical features of functional disorders of the cervix
- To describe the imaging features and basic clinical features of endometriosis
- To describe the imaging features and clinical features of uterine leiomyomas of different sizes
- To describe the image-guided therapeutic approaches to uterine leiomyomas
- To describe typical imaging features of the uterus after different types of gynaecological surgeries
- To describe typical imaging features of the uterus after different types of image-guided therapies

PREGNANCY

- To describe the imaging features and basic clinical features of uterine disorders associated with pregnancy
- To describe the imaging features and basic clinical features of uterine disorders during delivery
- To describe the imaging features and basic clinical features of uterine disorders in the post-partum period
- To describe the image-guided therapeutic approaches in severe post-partum bleeding
- To describe imaging strategies in pregnant patients with symptoms of an acute abdomen
- To describe typical imaging and clinical features in pregnant patients with symptoms of an acute abdomen
- To describe the principles of MR pelvimetry
- To list the relevant parameters of MR pelvimetric measurements
- To describe the principles of fetal MRI technology
- To have a basic understanding of the various stages of embryonic and fetal development and their respective appearance on MRI

OVARIES / ADNEXA / INFERTILITY

- To describe the procedure, possible complications, choice of contrast agent, indications and contraindications of hysterosalpingography
- To describe the different phases of hysterosalpingography
- To describe the imaging features and basic clinical features of ovarian cysts
- To describe the imaging features and basic clinical features of benign ovarian tumours
- To describe the imaging features and basic clinical features of malignant ovarian tumours
- To understand the MRI features of malignant ovarian tumours, including the O-RADS algorithm
- To describe the imaging features and basic clinical features of functional disorders of the ovaries
- To describe the imaging features and basic clinical features of inflammatory disorders of the tubes
- To describe the imaging features and basic clinical features of tumours of the tubes
- To describe the imaging work-up and features of infertility
- To describe the imaging features and basic clinical features of ovarian torsion
- To describe the imaging features and basic clinical features of changes and disorders of the ovaries associated with pregnancy and the post-partum period
- To describe typical imaging features of the ovaries after different types of gynaecological surgeries
- To describe typical imaging features of the ovaries after different types of image-guided therapies

PELVIC FLOOR

- To list imaging techniques that can be used to visualise the female pelvic floor
- To describe the imaging features and basic clinical features of descensus uteri and pelvic prolapsed
- To describe factors responsible for female urinary incontinence

SKILLS

- To choose the most appropriate imaging examination according to the clinical problem in gynaecological and obstetric radiology
- To choose the most suitable contrast material and its optimal use according to the imaging technique, the clinical problem and the age in gynaecological and obstetric radiology
- To confidently perform a transabdominal and/or transvaginal ultrasound in gynaecological disorders
- To confidently perform a transabdominal and/or transvaginal ultrasound in pregnant patients
- To perform hysterosalpingography
- To confidently plan a CT examination in gynaecological and obstetric radiology and to tailor it to the individual situation with a dose as low as reasonably achievable
- To confidently plan an MRI examination in gynaecological and obstetric radiology and to tailor it to the individual situation of the patient in regard to the potential use of intravenous contrast medium and spatial resolution
- To perform a pelvimetric MR examination in the pregnant patient
- To observe and/or perform under supervision image-guided drainage procedures in the urogenital tract

- To confidently perform proper post-processing tasks of examinations in paediatric urogenital radiology, including multiplanar reformations (MPR), maximum intensity projections (MIP), minimum intensity projections (MinIP) and fusion images

COMPETENCES AND ATTITUDES

- To justify diagnostic imaging examinations and/or interventional procedures of the female reproductive organs
- To choose the best-suited method for evaluating disorders of the female reproductive organs
- To communicate with the patient in order to obtain informed consent prior to diagnostic imaging and interventional procedures of the female reproductive organs
- To choose optimal imaging parameters for radiographic, ultrasonographic, CT and MRI examinations of the female reproductive organs
- To apply techniques to reduce exposure doses for radiographic and CT examinations of the female reproductive organs
- To choose the optimally suited imaging modality for pregnant patients
- To design imaging protocols for CT examinations of the female reproductive organs and for staging in patients with tumours of the female reproductive organs
- To design imaging protocols for MRI examinations of the female reproductive organs including the appropriate application of intravenous and/or intraluminal contrast and spatial and temporal resolution
- To supervise and teach technical staff to ensure that appropriate images of the female reproductive organs are obtained
- To interpret and report radiographs, CT and MRI examinations of patients with disorders of the female reproductive system
- To report oncological studies in patients with tumours of the female reproductive system according to international standards (FIGO, RECIST, WHO) applicable to the specific situation
- To appreciate own limitations and to identify when it is appropriate to obtain assistance in interpreting and reporting images of the female reproductive system
- To confidently identify urgent and/or unexpected findings in imaging examinations of the female reproductive system and to communicate these timely and properly
- To emphatically communicate with patients and their relatives in order to explain imaging findings in disorders of the female reproductive system
- To perform at multidisciplinary conferences and tumour boards for diseases of the female reproductive system

B-II-7 HEAD AND NECK RADIOLOGY

Content reviewed by ESHNR (European Society of Head and Neck Radiology)

INTRODUCTION

In Level II the trainee should, in addition to the knowledge, competencies and skills acquired in the first 3 years of training, have in-depth knowledge of the following:

- Advanced imaging modalities and their best use in specific clinical indications
- Expected changes after surgery, radiation and interventional procedures
- Imaging manifestations of benign and malignant diseases and the interpretation of signs on imaging that indicate the severity of disease and how this influences management

Trainees should be able to perform, interpret and report on head and neck radiographs, ultrasound, CT and MRI for common clinical indications as well as rare clinical indications (under supervision).

KNOWLEDGE

NORMAL ANATOMY

- To have a good knowledge of the anatomy and function of the temporal bone and its structures, skull base, cranial nerves, orbits and visual pathways, facial skeleton, sinuses, pharynx, oral cavity, mandible, teeth, temporomandibular joints, salivary glands, larynx, neck, deep spaces of the face and neck, thoracic inlet and brachial plexus, as well as the thyroid gland and parathyroid glands
- To be able to describe typical normal variants of the temporal bone, skull base, cranial nerves, orbits and visual pathways, facial skeleton, sinuses, pharynx, oral cavity, mandible, teeth, temporomandibular joints, salivary glands, larynx, neck, deep spaces of the face and neck, thoracic inlet and brachial plexus, as well as the thyroid gland and parathyroid glands and to differentiate these from disease

TEMPORAL BONE

- To describe typical imaging features of congenital disorders leading to deafness (e.g., cochlear aplasia/hypoplasia, Mondini malformation, large endolymphatic sac anomaly (LESA) / large vestibular aqueduct syndrome (LVA))
- To describe typical imaging features of disorders leading to secondary deafness including otosclerosis and Menière's disease
- To describe typical imaging features and basic clinical features of tumours of the temporal bone and cerebellopontine angle and to distinguish these from each other

- To describe typical imaging features and basic clinical features of traumatic lesions of the temporal bone
- To describe typical imaging features, basic clinical features and complications of middle ear inflammatory disease and cholesteatoma
- To describe typical pathologies of the external auditory canal, including atresia, infection and tumorous lesions
- To differentiate typical pathologies of the middle ear
- To have a basic understanding of the different types of cochlea and other auditory implants and their respective MRI compatibility/non-compatibility (including specific precautions)
- To list the various causes of vascular tinnitus and to describe their respective imaging features

FACIAL SKELETON, SKULL BASE AND CRANIAL NERVES

- To list the different neoplasms of the clivus and to describe their typical imaging appearance, including meningioma, macroadenoma and clivus chordoma
- To describe the typical imaging features and basic clinical features of lesions of the jugular foramen, including glomus tumour / paraganglioma, IX-XI schwannoma and jugular foramen meningioma and to distinguish from pseudolesions such as jugular bulb diverticulum and dehiscent jugular bulb
- To describe the typical imaging features and basic clinical features of intrinsic bony diseases of the skull base, including fibrous dysplasia, plasmocytoma, Langerhans cell histiocytosis, chondrosarcoma and metastases
- To list and categorise typical traumatic lesions of the facial skeleton and to be familiar with complications and therapeutic consequences
- To describe the typical imaging features of neoplasms of the mandible and maxilla
- To understand the typical imaging features of dentigerous cysts and odontogenic keratocysts
- To understand the imaging features of infectious and inflammatory lesions of the mandible, maxilla and skull base, including osteomyelitis
- To understand the imaging and clinical features of neoplastic, infectious and inflammatory involvement of the cranial nerves

ORBIT AND VISUAL PATHWAYS

- To describe the typical imaging features and basic clinical features of congenital lesions of the orbit, including coloboma
- To describe the typical imaging features and basic clinical features of typical tumours of the orbit in children including dermoid and epidermoid cysts, cavernous haemangioma, lymphangioma, rhabdomyosarcoma and retinoblastoma
- To describe the typical orbital manifestations of neurofibromatosis type I
- To describe the typical imaging features and basic clinical features of infectious and inflammatory disorders of the orbits including optic neuritis, abscesses, sarcoidosis and idiopathic inflammatory disorders
- To describe the typical imaging features and basic clinical features of benign tumours of the orbits including meningioma, optic nerve / chiasmal glioma, orbital haemangioma and benign mixed tumour of the lacrimal gland
- To describe the typical imaging features and basic clinical features of malignant tumours of the orbits including ocular melanoma, orbital lymphoma, higher grade optic nerve / chiasmal glioma, adenoid cystic carcinoma of the lacrimal glands

NOSE, NASOPHARYNX AND PARANASAL SINUSES

- To describe the typical imaging features and basic clinical features of congenital lesions of the paranasal sinuses including choanal atresia and frontoethmoidal encephalocele
- To differentiate typical normal variants of the nose and paranasal sinuses from pathology
- To describe the typical imaging features and basic clinical features of infectious and inflammatory disorders of the nose and paranasal sinuses including acute and chronic rhinosinusitis, fungal sinusitis, sinonasal polyposis, sinonasal mucocele and sinonasal granulomatosis with polyangiitis
- To be aware of typical complications of infectious and inflammatory disorders of the nose and paranasal sinuses
- To list and describe the typical surgical approaches to the nose and paranasal sinuses including functional endoscopic sinus surgery (FESS)
- To describe the common imaging features and basic clinical features of benign and malignant neoplasms of the nose and paranasal sinuses including inverted papilloma, juvenile angiofibroma, sinonasal hemangioma, sinonasal osteoma, sinonasal fibrous dysplasia, sinonasal squamous cell carcinoma, sinonasal adenocarcinoma, sinonasal melanoma, esthesioneuroblastoma and sinonasal lymphoma
- To describe the typical imaging features of the nose and paranasal sinuses after surgery
- To describe the typical imaging features and basic clinical features of non-neoplastic nasopharyngeal pathology including Thornwaldt cyst, inflammatory and infectious lesions
- To describe the typical imaging features and basic clinical features and understand patterns of spread of nasopharyngeal carcinoma

MASTICATOR SPACE, PAROTID SPACE AND CAROTID SPACE

- To describe the anatomical delineations of the masticator space, parotid space and carotid space
- To describe pseudolesions of the masticator space, including denervation atrophy, benign muscle hypertrophy and asymmetries of the pterygoid venous plexus
- To describe the typical imaging features of abscess formations of the masticator space
- To describe the typical imaging features and basic clinical features of benign and malignant neoplasms of the masticator space including peripheral nerve sheath tumours of the trigeminal nerve
- To describe the typical imaging features and basic clinical features of infectious and inflammatory lesions of the parotid space including parotitis, Sjogren syndrome and benign lymphoepithelial lesions in patients with HIV
- To describe the typical imaging features and basic clinical features of benign and malignant neoplasms of the parotid space including Warthin tumour, benign mixed tumour, adenoid cystic carcinoma, mucoepidermoid carcinoma, lymphoma, lymph node metastases and malignant tumours of the skin invading the parotid
- To describe the typical imaging features and basic clinical features of vascular lesions of the carotid space including ectatic carotid arteries, carotid artery pseudoaneurysm, carotid artery dissection and jugular venous thrombosis
- To describe the typical imaging features and basic clinical features of neoplasms of the carotid space including carotid body paraganglioma, glomus vagale paraganglioma, schwannoma and neurofibroma

LYMPH NODES OF THE HEAD AND NECK REGION

- To have an in-depth understanding of the nomenclature of the lymph nodes and nodal regions
- To describe the typical imaging features and basic clinical features of infectious and inflammatory disorders of the lymph nodes

- To describe the typical imaging features and basic clinical features of neoplastic disorders of the lymph nodes, including lymphoma (Hodgkin and Non-Hodgkin) and nodal metastases
- To be familiar with PET/CT imaging findings in benign and malignant lymph nodes

ORAL CAVITY, OROPHARYNX AND RETROPHARYNGEAL SPACE

- To describe the imaging features and clinical features of congenital lesions of the oral cavity and oropharynx, including dermoid and epidermoid cysts, accessory salivary tissue, lymphangioma, herniated sublingual salivary gland and lingual thyroid gland
- To describe the imaging features and clinical features of inflammatory and infectious lesions of the oral cavity and oropharynx, including abscesses, retention cysts, sialoceles, sialadenitis and ranula
- To describe the imaging features and clinical features of benign and malignant neoplasms of the oral cavity and oropharynx, including squamous cell carcinoma, lymphoma, benign mixed tumours, and malignant tumours of the minor salivary glands
- To describe the imaging features and clinical presentation of retropharyngeal abscesses and differentiate from retropharyngeal inflammation, oedema or prevertebral abscess
- To describe the imaging features of foreign body in the upper aerodigestive tract

HYPOPHARYNX AND LARYNX

- To describe the typical imaging features and basic clinical features of neoplasms of the hypopharynx and larynx, including squamous cell carcinoma of the hypopharynx, squamous cell carcinomas of the supraglottic, glottic and subglottic regions, and chondrosarcoma of the larynx
- To describe the typical imaging features of the hypopharynx and larynx after surgery and after radiation
- To describe the typical imaging features and relevant imaging anatomy of vocal cord paralysis
- To describe the potential effects and the respective imaging features of laryngeal trauma
- To list the typical imaging features, causes and clinical consequences of laryngeal tracheal stenoses
- To describe the typical imaging features of laryngoceles and pharyngoceles
- To describe typical functional abnormalities of the larynx and hypopharynx during impaired swallowing including primary and secondary aspiration and dysfunction of the crico-pharyngeal muscle
- To be familiar with typical PET/CT findings in head and neck tumours involving the pharynx, larynx and oral cavity and to understand common pitfalls of image interpretation

THYROID AND PARATHYROID GLANDS AND CERVICAL OESOPHAGEAL LESIONS

- To describe the typical imaging features and basic clinical features of thyroiditis, multinodular goiter, benign and malignant neoplasms of the thyroid follicular adenoma, parathyroid glands, including thyroid and parathyroid adenomas, different types of thyroid carcinoma and thyroid lymphoma
- To describe the typical imaging features and basic clinical features of cervical oesophageal carcinoma
- To describe the imaging features and basic clinical features of a Zenker diverticulum and the typical approaches to therapy
- To understand the differing roles and typical imaging findings of ultrasound, nuclear medicine, (4D) CT and MRI in parathyroid localisation
- To be familiar with the most important findings and the role of Tc-99m-scintigraphy in functional diseases of the thyroid gland

CONGENITAL AND TRANSSPATIAL LESIONS

- To have a basic understanding of the embryology of the head and neck region
- To describe the typical imaging features and basic clinical features of branchial cleft cysts
- To describe the typical imaging features and basic clinical features of thyroglossal duct cysts
- To describe the typical imaging features and basic clinical features of thymic cysts
- To describe the typical imaging features and basic clinical features of vascular lesions including malformations of the head and neck region
- To be familiar with the imaging manifestations of neurocutaneous syndromes, including neurofibromatosis type I in the head and neck

SKILLS

- To choose the most appropriate imaging examination according to the clinical problem in head and neck imaging
- To perform dynamic functional studies including video-fluoroscopy of the swallowing mechanism
- To ascertain correct positioning for imaging studies of the skull, sinus, skull base and facial bones including special views
- To confidently perform ultrasound including Doppler sonography of the neck, tongue, thyroid and salivary glands
- To confidently perform percutaneous FNAC or tru-cut biopsy, guided by ultrasound in straightforward / technically easy cases
- To observe and/or perform under supervision percutaneous biopsy and fine needle aspiration biopsy guided by ultrasound, CT and/or MRI in more complex head and neck cases
- To confidently plan a CT examination of the head and neck, including a perfusion acquisition and to tailor the CT to the individual situation regarding intravenous contrast medium, rate of injection, dose and delay of the contrast medium, with a dose as low as reasonably achievable
- To confidently plan an MRI examination of the head and neck including diffusion sequences and to tailor the MRI examination to the individual situation with regard to the potential use of intravenous contrast medium, rate of injection, dose and delay of the contrast medium, and spatial resolution
- To confidently plan a cone beam CT examination of the head and neck
- To apply basic techniques for quantification in head and neck disorders with ultrasound, CT and MRI, based on an understanding of their clinical role and limitations, such as measuring tumour volume, ADC values
- To perform proper post-processing tasks for head and neck imaging studies, including multiplanar reformations (MPR), maximum intensity projections (MIP), minimum intensity projections (MinIP), vessel analysis tools, endoluminal reconstructions, 3D reconstructions including volume rendering, and multimodality fusion of images

COMPETENCES AND ATTITUDES

- To confidently justify diagnostic imaging examinations and/or interventional procedures of the head and neck region
- To confidently choose the best-suited method for evaluating disorders of the head and neck region
- To communicate with the patient in order to obtain informed consent prior to diagnostic imaging and interventional procedures of the head and neck region

- To confidently choose the optimal imaging parameters for radiographic, ultrasonographic, CT, cone beam CT and MRI examinations of the head and neck region
- To confidently apply techniques to reduce exposure doses for radiographic, CT and cone beam CT examinations of the head and neck region
- To confidently design imaging protocols and standard operating procedures for CT and cone beam CT examinations of the head and neck region, including the appropriate application of intravenous contrast, spatial and temporal resolution
- To confidently design imaging protocols and standard operating procedures for MRI examinations of the head and neck region, including the appropriate application of intravenous contrast, spatial and temporal resolution
- To judge the quality of the imaging examinations in the head and neck and to devise strategies to improve image quality
- To confidently interpret and report radiographs, ultrasonographic examinations, CT studies, cone beam CT studies and MRI examinations of the most common and typical head and neck pathologies
- To report oncological studies of the head and neck region according to international standards (e.g., TNM) applicable to the specific situation
- To appreciate own limitations and to identify when it is appropriate to obtain assistance in interpreting and reporting images of the head and neck region
- To confidently identify urgent and/or unexpected findings in imaging examinations of the head and neck region and to communicate these timely and properly
- To empathically communicate with patients and their relatives in order to explain the imaging findings of the head and neck region, in particular also when dealing with “bad news”
- To take an active part in multidisciplinary conferences and tumour boards for diseases of the head and neck region

B-II-8 INTERVENTIONAL RADIOLOGY

Content reviewed by CIRSE (Cardiovascular and Interventional Radiological Society of Europe)

INTRODUCTION

In Level II the trainee should, in addition to the knowledge, competencies and skills acquired in the first 3 years of training, have in-depth knowledge of the following:

- Normal anatomy and common variants of the relevant body systems
- Common complications of procedures, including allergic reactions and their management
- Pre-procedure planning / workup (including the CIRSE checklist) i.e., blood coagulation, antibiotics, fluid management and plans for post-procedural care
- How to use the common pre-/peri- and post-procedural drugs
- Indications and contraindications for the relevant procedures
- Outcomes of common procedures, in particular technical and clinical success rate and where appropriate recurrence

NON-INVASIVE VASCULAR IMAGING

- To know the role of the different non-invasive imaging modalities in managing patients with vascular disease such as PAD, stroke, trauma and GI bleeding i.e., Duplex, MR, CT and nuclear imaging including PET/CT
- To describe the vascular anatomy on Duplex ultrasound, including both arterial and venous examinations
- To describe the characteristics of normal and abnormal Doppler waveforms
- To describe the typical imaging features on Doppler sonography of atherosclerotic disease, vasculitis, aneurysm disease, thrombosis, embolism and other vascular pathological conditions
- To describe the relevant acquisition parameters of CTA, including contrast materials used and reconstruction techniques
- To be aware of the radiation doses for CTA and to describe methods of reducing these
- To discuss advantages and disadvantages of CTA versus other techniques
- To describe the imaging features on CTA of atherosclerotic disease, vasculitis, aneurysmal disease, thrombosis, embolism and other vascular pathological conditions
- To understand the physical principles of MR angiography (MRA) techniques
- To discuss the advantages and disadvantages of different contrast agents used for MRA
- To discuss the differences between MRA techniques
- To discuss the advantages and disadvantages of MRA compared with other techniques
- To describe the role and use of hybrid/fusion imaging
- To have an in-depth understanding of nephrogenic systemic fibrosis (NSF)
- To describe the typical imaging features on MRA of atherosclerotic disease, vasculitis, aneurysm disease, thrombosis, embolism and other vascular pathological conditions
- To know about the imaging strategies for follow-up after IR and surgical therapies for vascular diseases including EVAR

DIAGNOSTIC ANGIOGRAPHY/VENOGRAPHY

- To describe the basic chemistry of the different iodinated contrast materials used, and to discuss the advantages / disadvantages of each agent for angiography including CO₂ angiography
- To describe mechanisms to minimise nephrotoxicity in at-risk patients, such as patients with diabetes or renal impairment
- To describe the standard groin anatomy, including the position of the inguinal ligament and the femoral nerve, artery and vein
- To describe the Seldinger technique of arterial and venous puncture
- To describe the technique for guidewire, sheath and catheter insertions into the groin or other access sites
- To describe the technique of puncture site haemostasis, including manual compression and common closure devices
- To know about micro-access systems for arterial puncture
- To describe alternative sites of arterial puncture, such as radial, brachial, axillary and popliteal arteries
- To list guidewires, sheaths and catheters used for common diagnostic angiographic procedures
- To describe digital subtraction angiography techniques, road mapping and pixel shift techniques
- To describe the principles of peripheral vascular angiography
- To describe the principles of mesenteric, coeliac and renal angiography
- To describe the principles of abdominal aortography
- To describe the principles of thoracic aortography
- To describe the principles of carotid, vertebral and subclavian angiography
- To describe the principles of venography
- To describe the imaging features on diagnostic angiography of atherosclerotic disease, vasculitis, aneurysm disease, thrombosis, embolism and other vascular pathological conditions
- To describe the principles of corticosteroid prophylaxis

VASCULAR INTERVENTION

ARTERIAL

- To list the medical risk factors for atherosclerotic diseases
- To describe the clinical symptoms of peripheral arterial disease
- To describe the angioplasty balloon dynamics and the mechanism of action of angioplasty
- To list the drugs and dosages used during angioplasty
- To describe the principles of intra-arterial pressure studies
- To describe common angioplasty procedures, such as renal, iliac and femoral angioplasties
- To describe the basic mechanisms for stent deployment and to list the materials used for stent construction
- To list the indications for stent placement versus angioplasty
- To know about drug-based therapies, e.g., drug coated balloons and their indications
- To know about the use of stentgrafts in the treatment of aneurysm disease in small and large vessels
- To know the role of embolisation in different elective and emergency clinical situations i.e., Obstetrics / Gynaecology for fibroid embolisation and obstetric haemorrhage, traumatic, gastrointestinal, thoracic

and other causes of haemorrhage, vascular malformations and prostate artery embolisation

- To describe the technique of selective angiography
- To list embolisation materials and their specific use
- To describe the relevant catheters and microcatheters used for embolisation
- To list the endpoints of embolisation
- To describe the treatment of post-embolic pain and post-embolic syndrome

VENOUS

- To describe the indications, types and techniques for the insertion of peripherally inserted central catheter (PICC) lines, Hickman catheters, dialysis catheters and ports
- To describe the technique of access to peripheral i.e., basilic etc; femoral, jugular and subclavian veins
- To know the role of IR in superior vena cava syndrome
- The role of IR in thrombo-embolic disease including pulmonary embolism and acute DVT
- The role of IR in chronic venous obstruction
- The role of IR in gonadal vein embolisation.
- To list the indications for caval filter placement
- To know about the different cava filter types available, including the difference between permanent and retrievable filters

HAEMODIALYSIS

- To describe the technique of access for haemodialysis grafts and fistulas for intervention
- To describe the techniques of thrombectomy, venoplasty and stenting
- To list the success rates and complications of thrombectomy, venoplasty and stenting
- To describe the post-procedural care after thrombectomy, venoplasty and stenting

TIPS

- To be familiar with indications for transjugular intrahepatic portosystemic shunt (TIPS) and balloon-occluded retrograde transvenous obliteration (BRTO), the techniques and complications

NON-VASCULAR INTERVENTIONS IN THE CHEST, GASTRO-INTESTINAL TRACT AND HEPATOBILIARY SYSTEM

- To list needles used for biopsy procedures, including fine gauge needles, large gauge needles and true-cut biopsy
- To list the indications for fine needle biopsy versus large gauge or core biopsy
- To know about co-axial and plugged biopsies
- To know about transjugular biopsies
- To know the patient selection criteria for image-guided drainage procedures in different organ systems
- To know the range of percutaneous drainage systems available and how to use them
- To know about trocar and over-the-wire techniques for drainage procedures
- To know about the different drainage catheter fixation systems and how to use them

- To describe how to carry out an abdominal, pelvic and organ abscess drainage
- To describe the methods of chest tube placement
- To describe underwater seal drainage systems
- To know about the fibrinolytic agents used in patients with loculated or complex empyemas or abscesses
- To list situations where more than one catheter is required
- To know the indications and contraindications for biliary drainage and stenting
- To describe the integration of ultrasound, CT and MRCP to plan an appropriate biliary drainage procedure
- To describe the performance of percutaneous transhepatic cholangiography
- To describe the types and method of use of coaxial access systems for biliary drainage
- To list the catheters used for biliary decompression
- To describe the technique of percutaneous biliary drainage
- To know about the use of the different biliary stents
- To describe the technique for biliary stent placement
- To understand the indications and contraindications of different stents (covered and uncovered stents) used in the palliation of oesophageal, stomach, small bowel and large bowel obstructions
- To describe the role of percutaneous gastrostomy and jejunostomy for nutrition

INTERVENTIONS IN THE GENITO-URINARY TRACT AND RENAL TRANSPLANT

- To describe the integration of ultrasound, CT and urographic studies to plan an appropriate nephrostomy
- To describe the pre-procedural work-up including coagulation screens and antibiotic regimens
- To describe the ultrasound / fluoroscopic guidance mechanisms for percutaneous nephrostomy
- To list the catheters used for percutaneous nephrostomy
- To describe the placement of percutaneous nephrostomy tubes
- To describe the complications of percutaneous nephrostomy
- To describe the aftercare, including catheter care and removal
- To describe antegrade ureteric stenting
- To know about the management of stone disease
- To understand the role of the different imaging modalities in transplant patients
- To know about the role of IR and imaging in patients following transplantations

INTERVENTIONAL RADIOLOGY OF THE MUSCULOSKELETAL SYSTEM

- To know the role of intra-articular joint injections
- To know about percutaneous osteoplasty
- To know about percutaneous ablation of bone and soft tissue lesions
- To know about interventional procedures for vertebral fractures
- To know about spinal procedures for disc, nerve and facet joint pathologies

INTERVENTIONAL ONCOLOGY

- To know the different relevant tumour classification systems and guidelines
- To know the patterns of tumour recurrence and nodal spread
- To know about the different treatment options (surgery, systemic treatment, radiation therapy) for common cancers according to guidelines
- To know the different available options in percutaneous treatment i.e., thermal and non-thermal therapies, including chemical agents
- To know about the different available options in intra-arterial treatments (embolisation, chemoembolisation, intra-arterial chemotherapy, radioembolisation)
- To know about techniques for increasing future liver remnant (portal vein embolisation, venous deprivation)

SKILLS

- To confidently treat both minor and major allergic reactions to iodinated contrast media
- To treat potential puncture site complications
- To perform duplex ultrasound, including both arterial and venous examinations
- To perform common Doppler examinations, including carotid Doppler, hepatic and renal Doppler studies and lower extremity venous duplex examinations
- To perform the Seldinger technique of arterial and venous puncture
- To perform guidewire, sheath and catheter insertions into the groin
- To perform puncture site haemostasis, including manual compression and using common closure devices
- To perform arterial puncture at alternative sites, such as radial brachial, axillary and popliteal arteries
- To carry out common diagnostic angiographic procedures
- To perform digital subtraction angiography techniques, bolus chase techniques, road mapping and pixel shift techniques
- To perform peripheral vascular angiography
- To perform mesenteric, coeliac and renal angiography
- To perform abdominal aortography
- To perform thoracic aortography
- To perform under supervision carotid, vertebral and subclavian angiography
- To perform venography
- To perform common angioplasty procedures, such as iliac, femoral and popliteal angioplasties under supervision
- To perform intra-arterial pressure studies
- To perform arterial stenting under supervision
- To observe and/or perform under supervision the placement of peripherally inserted central catheter (PICC) lines, Hickman catheters, dialysis catheters and ports
- To observe and/or perform under supervision haemodialysis shunt interventions
- To observe and/or perform under supervision venoplasty and stenting
- To observe and/or perform under supervision caval filter placement
- To observe and/or perform under supervision embolisation for indications such as acute bleeding, tumour therapy, AVM
- To observe and/or perform under supervision ablative therapy of soft tissue and/or bone tumour

- To perform selective angiography
- To effectively treat post-embolic pain and post-embolic syndrome
- To observe and/or perform under supervision transjugular intrahepatic portosystemic shunt (TIPS)
- To perform transcutaneous, image-guided biopsy procedures, including fine gauge needle biopsies, large gauge needle biopsies and trucut biopsy
- To perform chest drainage, fluid aspiration and abscess drainage
- To use underwater seal drainage systems
- To perform the trocar and Seldinger techniques for catheter placement
- To perform abdominal and pelvic abscess drainage
- To perform transhepatic cholangiography
- To perform under supervision biliary drainage
- To perform emergency procedures in life-threatening disorders, including cardio-pulmonary resuscitation

COMPETENCES AND ATTITUDES

- To appropriately select patients for a requested interventional procedure through a review of available history, imaging, laboratory values, and proposed or expected outcomes of the procedure
- To confidently identify features in the history or physical findings that would require pre-procedure assistance from other specialty disciplines, such as cardiology, anaesthesia, surgery or internal medicine
- To confidently identify risk factors from the patient's history, physical or laboratory examinations that indicate potential risk of bleeding, nephrotoxicity, cardiovascular problems, breathing abnormalities or adverse drug interactions during or after the procedure
- To obtain informed consent after discussion of the procedure with the patient, including a discussion of risks, benefits and alternative therapeutic options
- To correctly manage the monitoring of the patient during the radiological intervention and to recognise abnormalities and physical signs or symptoms that need immediate attention during the procedure
- To reduce accidental exposure to blood and body fluids in the interventional radiology suite
- To appreciate own limitations and to identify when it is appropriate to obtain assistance in interventional procedures
- To effectively manage and coordinate emergency situations arising from and/or during interventional procedures
- To communicate with patients and their relatives in order to explain the outcome of the interventional procedure
- To perform at multidisciplinary conferences for patients with potential indications for interventional procedures

B-II-9 MUSCULOSKELETAL RADIOLOGY

Content reviewed by ESSR (European Society of Musculoskeletal Radiology)

INTRODUCTION

In Level II the trainee should, in addition to the knowledge, competencies and skills acquired in the first 3 years of training, have in-depth knowledge of the following:

- Normal anatomy and common variants of the musculoskeletal system
- Advanced imaging modalities and their best use in specific clinical indications reducing exposure doses when applicable
- Imaging characteristics in trauma
- Imaging characteristics in infection, tumours and tumour-like lesions
- Imaging characteristics in haematological disorders, metabolic, endocrine and toxic disorders
- Imaging characteristics in arthropathies
- Imaging characteristics in developmental and paediatric disorders
- Algorithm analysis and performance of soft tissue, joint and bone interventional procedures

The trainee must be competent to confidently justify diagnostic imaging examinations and/or interventional procedures of the musculoskeletal system.

KNOWLEDGE

- To have an in-depth knowledge of the normal anatomy of all structures relevant to musculoskeletal imaging
- To have an in-depth knowledge of normal skeletal variants that may mimic disease
- To have an in-depth understanding of the development of the immature skeleton
- To have a basic understanding of the embryology of the skeleton
- To list the indications, contraindications and potential hazards (especially radiation hazards) of procedures and techniques relevant to musculoskeletal disease and trauma
- To have a basic clinical knowledge of medical, surgical and pathological conditions as well as pathophysiology related to the musculoskeletal system
- To describe the distinctive imaging features and clinical manifestations of musculoskeletal disease and trauma, as demonstrated by conventional radiography, CT, MRI, arthrography, radionuclide investigations and ultrasound
- To discuss differential diagnoses relevant to the clinical presentation and imaging appearance of musculoskeletal disease and trauma

TRAUMA – ACUTE AND CHRONIC

- To list the types and general classifications of fractures and dislocations
- To describe the typical imaging features and basic clinical features of fractures and dislocations in the adult skeleton

- To describe the typical imaging features and basic clinical features of fractures and dislocations in the immature skeleton
- To describe the typical imaging features and basic clinical features of articular fractures and dislocations including chondral and osteochondral lesions and osteochondritis dissecans
- To describe the distinctive imaging features and basic clinical features of healing and complications of fractures and dislocations, including delayed union, non-union, avascular necrosis, reflex sympathetic dystrophy / complex regional pain syndrome and myositis ossificans
- To describe the typical imaging features and basic clinical features of stress fractures, including fatigue, insufficiency and subchondral fractures
- To describe the typical imaging features and basic clinical features of avulsion fractures
- To describe the typical imaging features, imaging strategies and basic clinical features of pathological and non-accidental injury
- To describe the typical imaging features and basic clinical features of skull and facial bone fractures
- To describe the typical imaging features and basic clinical features of spinal fractures, including spondylolysis
- To describe the typical imaging features and basic clinical features of fractures and dislocations of the shoulder girdle, including sternoclavicular and acromioclavicular dislocations, clavicular fractures, scapular fractures and shoulder dislocation / instability
- To describe the typical imaging features and basic clinical features of fractures and dislocations of the upper limb including humeral fractures, elbow fractures and dislocations, proximal and distal forearm fractures and dislocations, wrist joint fractures / dislocations and hand fractures and dislocations
- To describe the typical imaging features and basic clinical features of fractures and dislocations of the pelvis including associated soft tissue injuries
- To describe the typical imaging features and basic clinical features of fractures and dislocations of lower limb including hip fractures and dislocations, femoral fractures, tibial and fibular fractures (including the ankle joint), hindfoot fractures, tarso-metatarsal fractures and dislocations and forefoot fractures and dislocations
- To describe the typical imaging features and basic clinical features of soft tissue injuries of the shoulder, including rotator cuff injuries, glenoid labrum injuries and biceps tendon injuries
- To describe the typical imaging features and basic clinical features of soft tissue injuries of the wrist including injuries of the triangular fibrocartilage complex
- To describe the typical imaging features and basic clinical features of soft tissue injuries of the knee, including meniscal injury, cruciate ligament injury and collateral ligament injury
- To describe the typical imaging features and basic clinical features of soft tissue injuries of the ankle including injuries of the principal tendons and ligaments

INFECTIONS

- To describe the typical imaging features and basic clinical features of acute, subacute and chronic osteomyelitis of the appendicular skeleton and of the spine
- To describe the typical imaging features and basic clinical features of post-traumatic and postoperative osteomyelitis
- To describe the distinctive imaging features and basic clinical features of tuberculosis of the musculoskeletal system

- To describe the typical imaging features and basic clinical features of infections of the spine (pyogenic and TB)
- To describe the typical imaging features and basic clinical features of infections of the appendicular skeleton
- To describe have a basic understanding of the imaging features of rarer infections (e.g., leprosy, brucellosis)
- To describe the typical imaging features and basic clinical features of infections with more common parasites worldwide (e.g., echinococcus)
- To describe the typical imaging features and basic clinical features of soft tissue infections
- To describe the typical imaging features and basic clinical features of HIV-associated infections

TUMOURS AND TUMOUR-LIKE LESIONS

- To understand and describe the typical imaging features, principles of tumour characterisation and staging of bone-forming tumours including osteoma and bone islands, osteoid osteoma and osteoblastoma and osteosarcoma (typical and common variants)
- To understand and describe the typical imaging features, principles of tumour characterisation and staging of cartilage-forming tumours including osteochondroma, enchondroma, chondroblastoma, chondromyxoid fibroma and chondrosarcoma (central and peripheral)
- To understand and describe the typical imaging features, principles of tumour characterisation and staging of tumours of fibrous origin including fibrous cortical defects and non-ossifying fibroma, fibrous dysplasia, fibrosarcoma and malignant fibrous histiocytoma
- To understand and describe the typical imaging features, principles of tumour characterisation and staging of haematopoietic and reticuloendothelial tumours including giant cell tumour, Langerhans cell histiocytosis, malignant round cell tumours (Ewing's sarcoma, lymphoma and leukaemia), myeloma and plasmocytoma
- To understand and describe the distinctive imaging features, principles of tumour characterisation and staging of tumour-like lesions including simple bone cysts and aneurysmal bone cysts
- To understand and describe the typical imaging features, principles of tumour characterisation and staging of metastases
- To confidently recognise "don't touch" lesions
- To understand and describe the typical imaging features, principles of tumour characterisation and staging of chordoma
- To understand and describe the typical imaging features, principles of tumour characterisation and staging of adamantinoma
- To understand and describe the typical imaging features, principles of tumour characterisation and staging of tumours of fat origin, including lipoma and liposarcoma
- To understand and describe the typical imaging features, principles of tumour characterisation and staging of tumours of neural origin including neurofibroma schwannoma and MPNST
- To understand and describe the typical imaging features, principles of tumour characterisation and staging of tumours of vascular origin, including haemangioma and to know the difference between tumours of vascular origin and vascular malformations
- To understand and describe the typical imaging features, principles of tumour characterisation and staging of soft tissue sarcomas

HAEMATOLOGICAL DISORDERS AND BONE MARROW ABNORMALITIES

- To describe the imaging features and basic clinical features of haemoglobinopathies including sickle cell disease and thalassaemia
- To describe the imaging features and basic clinical features of myelofibrosis
- To understand and describe imaging features and clinical impact of diffuse bone marrow abnormalities such as reconversion and cellular infiltration

METABOLIC, ENDOCRINE AND TOXIC DISORDERS

- To describe the imaging features and basic clinical features of rickets and osteomalacia
- To describe the imaging features and basic clinical features of primary and secondary hyperparathyroidism (including chronic renal failure)
- To describe the imaging features and basic clinical features of osteoporosis (including basic concepts of bone mineral density measurements) and fluorosis

JOINTS

- To have an in-depth knowledge of the imaging features and clinical features of degenerative disease of the spine, disc and facet joints
- To have an in-depth knowledge of the imaging features and clinical features of degenerative disease of the peripheral joints
- To have an in-depth knowledge of the imaging features and clinical features of inflammatory joint disease, including rheumatoid arthritis, juvenile rheumatoid arthritis, ankylosing spondylitis, psoriatic arthritis, enteropathic arthropathies and infective arthritis (pyogenic and tuberculous)
- To describe the imaging features and basic clinical features of crystal arthropathies, including pyrophosphate arthropathy, hydroxyapatite deposition disease and gout
- To describe the imaging features and basic clinical features of masses of the joints, including ganglion, synovial chondromatosis and pigmented villonodular synovitis
- To describe the imaging features and basic clinical features of neuroarthropathy, including diabetic foot, Charcot's joints and Pseudo-Charcot joint (steroid-induced)
- To describe the imaging features and basic clinical features of complications of prosthetic joint replacement (hip and knee) and the postoperative spine

CONGENITAL, DEVELOPMENTAL AND PAEDIATRIC

- To describe the imaging features and basic clinical features of congenital disorders of the spine, including scoliosis (congenital and idiopathic) and dysraphism
- To describe the imaging features and basic clinical features of congenital disorders of the shoulder, including Sprengel's deformity

- To describe the imaging features and basic clinical features of congenital disorders of the hand and wrist, including Madelung deformity (idiopathic and other causes)
- To describe the imaging features and basic clinical features of congenital disorders of the hip, including developmental dysplasia, irritable hip, Perthes disease and slipped upper femoral epiphysis
- To describe the imaging features and basic clinical features of femoroacetabular impingement
- To describe the imaging features and basic clinical features of congenital disorders of the ankle and foot
- To describe the imaging features and basic clinical features of congenital tarsal coalition
- To describe the imaging features and basic clinical features of bone dysplasias
- To describe the imaging features and basic clinical features of congenital disorders of multiple epiphyseal dysplasia
- To describe the imaging features and basic clinical features of congenital disorders of achondroplasia
- To describe the imaging features and basic clinical features of congenital disorders of osteogenesis imperfecta
- To describe the imaging features and basic clinical features of congenital disorders of the sclerosing disorders of the bone, including osteopetrosis, melorheostosis and osteopoikilosis
- To describe the imaging features and basic clinical features of tumour-like lesions in the paediatric age group, including diaphyseal aclasis, Hereditary Multiple Exostosis Syndrome, Maffucci's disease, and Ollier's disease
- To describe the imaging features and basic clinical features of the musculoskeletal manifestations of neurofibromatosis

MISCELLANEOUS

- To describe the imaging features and basic clinical features of Paget's disease
- To describe the imaging features and basic clinical features of sarcoidosis
- To describe the imaging features and basic clinical features of hypertrophic osteoarthropathy
- To describe the imaging features and basic clinical features of transient or regional migratory osteoporosis
- To describe the imaging features and basic clinical features of chronic non-bacterial osteomyelitis (chronic recurrent multifocal osteomyelitis)
- To describe the imaging features and basic clinical features of osteonecrosis
- To describe the principles of characterisation of soft tissue calcification / ossification

SKILLS

- To choose the most appropriate imaging examination according to the clinical problem in musculoskeletal imaging
- To choose the most suitable contrast material and its optimal use according to the imaging technique and the clinical problem in musculoskeletal imaging
- To perform dynamic functional studies of the spine and joints
- To perform a correct positioning for radiography of the spine and of the extremities including special views
- To perform ultrasound of the musculoskeletal system
- To perform image-guided biopsies in the musculoskeletal system in easy cases
- To observe and/or perform under supervision image-guided biopsies in the musculoskeletal system in more complex cases
- To confidently plan a CT examination of the musculoskeletal system and to tailor it to the individual situation, with a dose as low as reasonably achievable

- To confidently plan an MRI examination of the musculoskeletal system and to tailor it to the individual situation in regard to the potential use of intravenous contrast medium and spatial resolution
- To perform contrast injections in various joints, including the hip, shoulder and wrist for MR arthrography or CT arthrography
- To observe and/or to perform under supervision discography, facet joint injections and vertebroplasty
- To observe and/or to perform under supervision image-guided bone biopsy and drainage of the musculoskeletal system
- To confidently perform proper post-processing tasks of musculoskeletal imaging studies, including multiplanar reformations (MPR), maximum intensity projections (MIP), minimum intensity projections (MinIP) and fusion images

COMPETENCES AND ATTITUDES

- To confidently justify diagnostic imaging examinations and/or interventional procedures of the musculoskeletal system
- To confidently choose the best-suited method for evaluating disorders of the musculoskeletal system
- To communicate with the patient in order to obtain informed consent prior to diagnostic imaging and interventional procedures of the musculoskeletal system
- To confidently choose optimal imaging parameters for radiographic, ultrasonographic, CT and MRI examinations of the musculoskeletal system
- To confidently apply techniques to reduce exposure doses for radiographic and CT examinations of the musculoskeletal system
- To confidently design imaging protocols and standard operating procedures for CT examinations of the musculoskeletal system, including the appropriate application of intravenous contrast, positioning, spatial and temporal resolution
- To confidently design imaging protocols and standard operating procedures for MRI examinations of the musculoskeletal system, positioning, including the appropriate application of intravenous contrast, spatial and temporal resolution
- To supervise and teach technical staff to ensure that appropriate images of the musculoskeletal system are obtained
- To confidently judge the quality of imaging examinations in musculoskeletal imaging and to devise strategies to improve image quality
- To confidently interpret and report radiographs, ultrasonographic examinations, osteodensitometric studies, CT studies and MRI examinations of the musculoskeletal system
- To report oncological studies of the musculoskeletal system according to international standards (RECIST, WHO) applicable to the specific situation
- To appreciate own limitations and to identify when it is appropriate to obtain assistance in interpreting and reporting images of the musculoskeletal system
- To confidently identify urgent and/or unexpected findings in imaging examinations of the musculoskeletal system and to communicate these timely and properly
- To communicate with patients and their relatives in order to explain their imaging findings of the musculoskeletal system
- To perform at multidisciplinary conferences and tumour boards for diseases of the musculoskeletal system

B-II-10 NEURORADIOLOGY

Content reviewed by ESNR (European Society of Neuroradiology)

INTRODUCTION

In Level II the trainee should, in addition to the knowledge, competencies and skills acquired in the first 3 years of training, have in-depth knowledge of the following:

- Normal anatomy and common variants of the central and peripheral nervous system
- Different disease entities affecting the brain, skull, skull base, extracranial head, spine and spinal cord, and peripheral nervous system

The trainee must be able to confidently justify and choose the appropriate examination technique that is needed for the patient in question, adapted to the clinical situation.

The trainee should observe and/or perform under supervision doppler ultrasound examinations as well as different interventional procedures, such as DSA and percutaneous procedures.

KNOWLEDGE

NORMAL ANATOMY

- To have an in-depth understanding of the normal anatomy of the brain, skull, skull base, brain, extracranial head, spine, spinal cord and peripheral nervous system
- To confidently detect and describe normal imaging findings of the brain and spine on X-ray, ultrasound, CT and MRI
- To confidently delineate and describe the skull, skull base, and spine on conventional radiography
- To confidently delineate the cortex, white matter, basal ganglia, ventricles, cisterns and cranial nerves on CT and/or MRI of the brain
- To have knowledge of the functional anatomy of the motor, sensory and visual systems
- To have knowledge of the functional anatomy of the cognition and memory
- To have knowledge of the glymphatic system
- To confidently delineate the orbit and its contents, paranasal sinuses, temporal bone, salivary glands, neck lymph nodes, larynx, pharynx, thyroid and parathyroid glands, skull, skull base, and deep spaces of the neck on CT and/or MRI of the brain
- To confidently delineate the vertebral bodies, spinal canal, intervertebral discs, dural sac, spinal cord and cauda equina on CT and/or MRI of the spine

- To confidently delineate the aortic arch, carotid and vertebral arteries, intracranial arteries and the circle of Willis, spinal and spinal cord vascularisation on X-ray angiography, CT angiography and MR angiography
- To describe the normal imaging features of Virchow-Robin spaces
- To describe normal variants of skull, skull base, brain, extracranial head, spine, and spinal cord and differentiate these from pathology

CONGENITAL AND DEVELOPMENTAL ABNORMALITIES

- To describe the imaging features of malformations of the skull base and craniovertebral junction
- To describe anomalies of the oro-pharyngeal apparatus including branchial cleft cysts and thyroglossal duct cysts
- To describe the imaging features of malformations of cortical development, including focal cortical dysplasia, polymicrogyria, heterotopia (subependymal, focal subcortical, laminar), lissencephaly / pachygyria, (hemi) megalencephaly, microlissencephaly, schizencephaly
- To describe the imaging features of agenesis and dysgenesis of the corpus callosum and of holoprosencephaly (lobar, alobar, semilobar)
- To describe the imaging features of hindbrain and posterior fossa malformations, including the Chiari malformations, the Dandy-Walker spectrum and the molar tooth malformations (including Joubert syndrome)
- To describe the imaging features of preterm brain injury
- To describe the imaging features of intracranial and spinal arachnoid cysts
- To describe the imaging features of hypoxic ischemic encephalopathy of the mature infant after severe acute asphyxia
- To describe the imaging features of hypoxic ischemic encephalopathy of the mature infant after prolonged partial hypoxia
- To describe the imaging features of hypoxic ischemic encephalopathy of the term newborn
- To describe the imaging features of intracranial and spinal arachnoid cysts
- To describe the neuro-imaging features, extracranial manifestations, diagnostic criteria and clinical features of tuberous sclerosis, Sturge-Weber diseases, neurofibromatosis type I and II, and other common phakomatoses
- To describe the common imaging features of segmental vascular syndromes
- To describe the common imaging features of inherited metabolic conditions and leukodystrophies

NEUROVASCULAR

- To list the stroke subtypes and their causative mechanism in adults and paediatric patients
- To describe the relevance of the “time is brain” approach to the imaging evaluation of patients with stroke
- To describe comprehensive stroke evaluation parameters for MRI and CT, including diffusion-weighted imaging, CT perfusion, MR perfusion, CT angiography and MR angiography
- To list the CT and MR perfusion parameters relevant for stroke imaging and to describe their relevance and limitations
- To list and describe the main neuroradiological interventions in patients with acute ischaemic stroke

- To describe the diagnostic and therapeutic approach in patients with ischemic strokes of the posterior circulation / basilar artery occlusion
- To describe interventional approaches to intracranial and extracranial stenoses
- To describe the imaging features, relevant clinical features and imaging algorithm in patients with venous stroke / intracranial venous thrombosis
- To describe the imaging and clinical features in patients with subarachnoid haemorrhage (SAH)
- To describe the standard imaging evaluation algorithm in patients with spontaneous SAH
- To list the major complications and describe their respective imaging features in patients with spontaneous SAH
- To describe intracranial collateral circulation and their relevance in ischaemic stroke
- To describe the imaging features and relevant haemodynamic parameters in patients with vasospasm
- To describe the imaging features of atherosclerotic and hypertensive small vessel diseases
- To describe the imaging features of genetically determined small vessel diseases (CADASIL, Susac, Fabry, HERNIS)
- To describe the imaging features of cerebral amyloid angiopathy and cerebral amyloid angiopathy-related inflammation
- To describe the imaging features of arterial vessel wall abnormalities in atherosclerotic diseases of the intracranial and extracranial vessels
- To describe common imaging features in patients with migraine
- To differentiate atypical and typical intracerebral haemorrhages
- To list the major causes for atypical and typical intracerebral haemorrhages
- To describe the imaging algorithms in patients with atypical and typical intracerebral haemorrhages
- To list the different types of intracranial and extracranial vascular malformations
- To describe the imaging features and therapeutic approaches in patients with intracranial vascular malformations including arteriovenous malformations, dural arterio-venous fistulas and carotid-cavernous sinus fistulas
- To describe the imaging features, differential diagnoses and relevance of developmental venous anomalies
- To describe the imaging features, differential diagnoses and relevance of cavernous malformations
- To describe the imaging features, differential diagnoses and relevance of capillary telangiectasias
- To describe the imaging features of the different types of intracranial aneurysms: saccular, dissecting, fusiform, giant, infectious
- To describe the imaging features of intra / extracranial arterial dissections
- To describe the imaging features of posterior reversible encephalopathy syndrome
- To describe the imaging features of reversible cerebral vasoconstriction syndrome
- To describe the imaging features and basic clinical features of primary and systemic central nervous system vasculitis
- To describe cerebrovascular lesions related to arterial hypertension
- To describe the standard imaging evaluation and features of brain death
- To describe the imaging and clinical features in patients with venous occlusive disease
- To describe the imaging features of Moyamoya syndrome and Moyamoya disease

NEUROTRAUMA

- To list the typical imaging algorithms for patients with acute traumatic injury to the brain
- To describe the typical imaging features and basic clinical features of epidural hematoma
- To describe the typical imaging features and basic clinical features of subdural hematoma
- To describe the typical imaging features and basic clinical features of traumatic subarachnoidal hemorrhage
- To describe the imaging algorithms and imaging features of traumatic CSF leaks
- To describe the characteristic imaging features and basic clinical features of brain contusions
- To describe the characteristic imaging features and basic clinical features of diffuse axonal injury
- To describe the characteristic imaging features and warning signs for elevated intracranial pressure
- To describe the characteristic imaging features of fractures of the skull and skull base including the temporal bone, facial bones, the paranasal sinuses and the orbit
- To describe the characteristic imaging features and clinical features in children with non-accidental injury
- To describe the characteristic imaging features of vascular traumatic injury of the intra- and extracranial vessel

INTRACRANIAL TUMOURS

- To list the most common intracranial and extracranial tumours
- To have a good knowledge of the WHO classification of CNS tumours including their molecular parameters
- To describe the typical imaging manifestations of intracranial metastases of various primary tumours
- To describe the imaging features and basic clinical features of diffuse astrocytic and oligodendroglial tumours
- To describe the imaging features and basic clinical features of pilocytic astrocytomas
- To describe the imaging features and basic clinical features of pleomorphic xanthoastrocytoma
- To describe the imaging features, basic clinical features, location and association of subependymal giant cell astrocytomas
- To describe the imaging features, basic clinical features and location of neuronal and mixed neuronal-glial tumours including ganglioglioma, gangliocytoma, dysembryoplastic neuroepithelial tumour (DNET), dysplastic cerebellar gangliocytoma, desmoplastic infantile, desmoplastic infantile astrocytoma and ganglioglioma, rosette-forming glioneuronal tumour, neurocytoma and paraganglioma
- To properly identify tumour response and recurrence
- To describe the imaging features and basic clinical features of CNS tumours treatment-related (pseudoprogression and pseudoresponse)
- To list the characteristic imaging features and locations of the various forms of brain stem tumours
- To describe the imaging features and basic clinical features of optic pathway gliomas
- To describe the imaging features and basic clinical features of ependymal tumours
- To describe the imaging features and basic clinical features of the different genetic defined medulloblastomas and other embryonal tumours such as CNS neuroblastoma and atypical teratoid and rhabdoid tumours (ATRT)
- To describe the imaging features and basic clinical features of choroid plexus tumours
- To describe the imaging features and basic clinical features of primary and secondary lymphoma of the brain
- To describe the imaging features of leukemic involvement of the central nervous system

- To describe the imaging features of post-transplantation lymphoproliferative disease
- To describe the imaging features, basic clinical features and differential diagnosis of sellar and suprasellar region such as craniopharyngiomas and tuber cinereum hamartomas
- To describe the imaging features and basic clinical features of pituitary microadenomas and macroadenomas
- To describe the imaging features and basic clinical features of tumours of the pineal region
- To describe the imaging features and basic clinical features of typical and atypical meningiomas, and malignant meningiomas
- To describe imaging features of mesenchymal, non-meningothelial tumours, such as angiosarcomas, hemangiopericytomas, chondromas, chondrosarcomas, osteomas, osteosarcomas and hemangioblastomas
- To describe the imaging features and basic clinical features of histiocytic tumours including Langerhans cell histiocytosis, Erdheim-Chester disease, Rosai-Dorfman disease, juvenile xanthogranuloma and histiocytic sarcoma
- To describe the imaging features and basic clinical features of germ cell tumours such as germinomas, embryonal carcinomas and teratomas
- To describe the imaging features and basic clinical features of cranial nerves tumours including vestibular schwannoma/"acoustic neuroma", trigeminal schwannoma and facial nerve schwannoma
- To describe the imaging features and basic clinical features of perineural spread of malignant tumours
- To describe the imaging features and dissemination pathways of malignant and benign tumours of the suprahyoid neck and paranasal sinuses, including their potential spread patterns through the skull base
- To describe the imaging features and basic clinical features of orbital tumours
- To describe the imaging features and basic clinical features of temporal bone tumours
- To describe the imaging features and basic clinical features of salivary gland tumours
- To describe the imaging features and basic clinical features of thyroid and parathyroid tumours
- To describe the imaging features of chordoma of the clivus and other tumours of the skull base
- To describe the imaging features of tumours of the skull

NEUROINFLAMMATORY, NEUROINFECTIOUS AND NEURODEGENERATIVE DISORDERS

- To describe the imaging features of age-related changes of the brain
- To describe the typical and atypical imaging features and clinical features of multiple sclerosis (MS) and its variants, acute disseminated encephalomyelitis (ADEM) and neuromyelitis optica spectrum disorders (NMOSD)
- To differentiate the appearance of demyelinating lesions from age-related changes
- To describe the characteristic imaging features of treatment-related effects in patients with multiple sclerosis
- To describe the imaging features and clinical features of IRIS (immune reconstitution inflammatory syndrome)
- To describe the imaging features and clinical features of CLIPPERS
- To describe the imaging features and clinical features of neurosarcoidosis
- To describe the characteristic imaging features and clinical features of patients with dementia of the Alzheimer type, as well as of other primary neurodegenerative diseases, such as multi-system atrophy, and fronto-temporal dementia
- To have a basic understanding of the imaging features in Parkinson's disease and in atypical Parkinson

syndromes, and other movement disorders such as progressive supranuclear palsy

- To describe the imaging features and basic clinical features of amyotrophic lateral sclerosis
- To describe the imaging features and basic clinical features of degenerative ataxia disorders
- To describe the typical CNS imaging features and basic clinical features of Wilson disease
- To describe the imaging features and basic clinical features of acute and chronic hepatic encephalopathy, and chronic renal failure
- To describe the imaging features and basic clinical features of exogenous toxic (carbon monoxide poisoning, recreational drugs, ethanol abuse, organic solvents) and acquired metabolic conditions (osmotic demyelination syndrome, hyper / hypoglycemia, iron and B12 / copper deficiency)
- To have an in-depth understanding of the typical and atypical imaging features of herpes simplex virus (HSV) infections of the brain and understand the therapeutic concepts and urgency of HSV infections of the brain
- To describe the imaging features and the limitations of imaging in patients with meningitis
- To list the typical complications of meningitis and to describe their imaging features
- To describe the typical imaging features and basic clinical features of the different stages of intracranial abscess formation
- To describe the characteristic imaging features and basic clinical features of tuberculous meningitis and intracranial tuberculomas
- To describe the characteristic imaging features and basic clinical features of hemophagocytic lymphohistiocytosis
- To describe the characteristic imaging features and basic clinical features of hypophysitis
- To describe the characteristic imaging features and basic clinical features of IgG4-related disorders
- To have a basic understanding of congenital infections of the brain including toxoplasmosis, CMV, rubella and HSV
- To describe the characteristic imaging features and basic clinical features of sarcoidosis
- To describe the characteristic intracranial imaging features and basic clinical features of HIV infection of the brain
- To describe the characteristic intracranial imaging features and basic clinical features of typical complications of HIV infections
- To describe the characteristic imaging features and basic clinical features of prion infections
- To describe the characteristic imaging features and basic clinical features of fungal infections
- To describe the characteristic imaging features and causes of therapy-induced lesions to the CNS (e.g., after radiation therapy and after chemotherapy) such as radiation-induced leukoencephalopathy, radiation-induced tumours, radiation necrosis and SMART syndrome
- To describe the characteristic imaging features of autoimmune-mediated encephalitis

HYDROCEPHALUS

- To have a basic understanding of the production, flow and resorption of CSF
- To list and to differentiate the different types of hydrocephalus and their respective causes
- To describe the characteristic imaging features and clinical features of normal pressure hydrocephalus
- To describe the characteristic imaging features, causes and clinical features of non-communicating hydrocephalus

- To describe the characteristic imaging features, causes and clinical features of benign intracranial hypertension
- To describe the characteristic imaging features, causes and clinical features of CSF hypotension
- To describe the characteristic imaging features and list the major causes of aqueductal stenosis
- To describe the methods of qualitative and quantitative imaging-based flow assessment of the CSF
- To have a basic understanding of the different therapeutic approaches to hydrocephalus, including shunt placement and third ventriculostomy

SPINE AND SPINAL CORD

- To describe the imaging features and basic clinical features of spinal malformations including open and closed spinal dysraphisms
- To differentiate stable and unstable fractures of the spine
- To describe the characteristic imaging features and clinical features in spinal cord trauma
- To differentiate between benign and malignant vertebral compression fractures
- To describe the imaging features of myelopathy and to list its common causes
- To describe the characteristic imaging features of spinal instability
- To describe the characteristic imaging features of inflammatory condition of the spine: enthesopathies, DISH, Bechterew
- To describe the characteristic imaging features of spinal metastases including the criteria for cord compression
- To describe the characteristic imaging features of osteoporosis and metabolic diseases involving the spine
- To describe the characteristic imaging features and clinical features in spinal cord ischemia
- To describe the characteristic imaging features and clinical features of Hirayama disease
- To describe the characteristic imaging features and clinical features of transdural spinal cord herniation
- To list the most common intraspinal tumours
- To describe the imaging features and basic clinical features of spinal cord tumours (ependymoma, astrocytoma, haemangioblastoma)
- To describe the imaging features and basic clinical features of intradural spinal tumours (meningioma, neurinoma)
- To describe the imaging features and basic clinical features of transverse myelitis (TM)
- To describe the imaging features and basic clinical features of spinal manifestations of MS, acute disseminated encephalomyelitis (ADEM) and neuromyelitis optica spectrum disorders (NMOSD)
- To describe the imaging features and basic clinical features of infectious diseases of the spine and spinal cord including discitis and spondylodiscitis
- To describe the imaging features and basic clinical features of spinal vascular malformations
- To describe the imaging features and basic clinical features of syrinx formation and hydromyelia
- To describe the imaging features of chordomas and other primary tumours of the spine
- To have an in-depth knowledge of the imaging features of degenerative diseases of the spine disc and facet joints
- To describe percutaneous and endovascular interventional procedures of the spine/spinal cord

EPILEPSY

- To list the major causes of seizures in paediatric and adult population
- To describe the characteristic imaging evaluation algorithm in patients with seizures
- To describe the imaging features of mesial temporal sclerosis

- To describe the imaging features of status epilepticus
- To describe the value of neurofunctional imaging feature in the assessment of epilepsy

PERIPHERAL NERVOUS SYSTEM

- To describe the characteristic imaging evaluation algorithm and features of brachial plexopathy
- To describe the characteristic imaging evaluation algorithm and features of lumbosacral plexopathy
- To describe the characteristic imaging evaluation algorithm in patients with entrapment neuropathies
- To describe the imaging features of tumoural lesions of the peripheral nerves
- To describe the imaging features of inflammatory lesions of the peripheral nerves, including chronic inflammatory demyelinating polyradiculoneuropathy
- To describe the imaging features of hereditary motor and sensory neuropathies

SKILLS

- To choose the most appropriate imaging examination according to the clinical problem in neuroradiology
- To choose the most appropriate imaging strategy in the monitoring of CNS tumours
- To choose the most appropriate imaging strategy in the monitoring of multiple sclerosis
- To choose an appropriate interventional procedure (endovascular or percutaneous) according to the clinical problem in neuroradiology
- To choose the most suitable contrast material and its optimal use according to the imaging technique and the clinical problem in neuroradiology
- To observe and/or perform under supervision ultrasound of brain in the infant
- To observe and/or perform under supervision Doppler sonography of the intracranial vessels
- To observe and/or perform under supervision diagnostic neuroangiography
- To observe and/or perform under supervision intraarterial thrombectomy and other recanalisation procedures in patients with ischaemic stroke
- To observe and/or perform under supervision neurointerventional therapy in patients with acute basilar artery occlusion
- To observe and/or perform under supervision endovascular treatment of intracranial aneurysms
- To observe and/or perform under supervision spinal angiography
- To observe and/or perform under supervision percutaneous interventional procedures of the extracranial head
- To observe and/or perform under supervision disk, vertebral and facet interventional procedures included discography and biopsy
- To observe and/or to perform under supervision discography, facet joint injections and vertebroplasty
- To confidently plan a CT examination of the brain and spine and to tailor it to the individual situation, with a dose as low as reasonably achievable
- To confidently plan an MRI examination of the brain and spine and to tailor it to the individual situation in regard to the potential use of intravenous contrast medium and spatial resolution
- To plan and perform advanced CT and MRI examinations including perfusion CT and MR, diffusion tensor imaging, functional MRI (task-related and resting-state) and proton MR spectroscopy
- To confidently perform proper post-processing tasks of neuroradiological studies, including multiplanar reformations (MPR), maximum intensity projections (MIP), minimum intensity projections (MinIP), tractography, functional MRI and fusion images in regard to the potential use of intravenous contrast medium and spatial resolution

COMPETENCES AND ATTITUDES

- To confidently justify diagnostic imaging examinations and/or interventional procedures of the brain, skull, skull base, spine, spinal cord, extracranial head and peripheral nervous system
- To confidently choose the best-suited method for evaluating disorders of the brain, skull, skull base, spine, spinal cord, extracranial head, and peripheral nervous system
- To communicate with the patient in order to obtain informed consent prior to diagnostic imaging and interventional procedures of the brain, skull, skull base, spine, spinal cord, extracranial head and peripheral nervous system
- To confidently choose optimal imaging parameters for X-ray, ultrasound, CT and MRI examinations of the brain, skull, skull base, spine, spinal cord, extracranial head and peripheral nervous system
- To confidently apply techniques to reduce exposure doses for X-ray and CT examinations of the brain, skull, skull base, spine and extracranial head
- To design a time-saving imaging algorithm and to define standard operating procedures for imaging patients with stroke
- To confidently perform and interpret a comprehensive imaging evaluation in patients with acute stroke
- To confidently design imaging protocols and standard operating procedures for CT examinations of the brain, skull, skull base, extracranial head, spine, spinal cord, peripheral nervous system, including the appropriate application of intravenous contrast, positioning, spatial and temporal resolution
- To confidently design imaging protocols and standard operating procedures for MRI examinations of the brain and spine, including the appropriate application of intravenous contrast, spatial and temporal resolution
- To supervise and teach technical staff to ensure that appropriate images of the brain, skull, skull base, spine, spinal cord, extracranial head and peripheral nervous system are obtained
- To confidently judge the quality of imaging examinations in neuroradiology and to devise strategies to improve image quality
- To confidently interpret and report X-ray, ultrasound, CT and MRI examinations of the brain, skull, skull base, spine, spinal cord, extracranial head and peripheral nervous system
- To confidently use structured reporting in common clinical situations (eg. stroke, multiple sclerosis, brain tumours, dementia...)
- To confidently use visual scales to report global and regional brain atrophy
- To confidently use visual scales to report white matter abnormalities
- To report oncological studies according to international standards applicable to the specific situation
- To appreciate own limitations and to identify when it is appropriate to obtain assistance in interpreting and reporting images of the brain, skull, skull base, extracranial head, spine, spinal cord and peripheral nervous system
- To confidently identify urgent and/or relevant unexpected findings in imaging examinations of the brain, skull, skull base, extracranial head, spine, spinal cord and peripheral nervous system, and to communicate these timely and properly
- To communicate with patients and their relatives in order to explain their imaging findings of the brain, skull, skull base, spine, spinal cord, extracranial head and peripheral nervous system
- To participate in and/or conduct multi-disciplinary conferences, vascular boards, and tumour boards for diseases of the brain, skull, skull base, extracranial head, spine, spinal cord and peripheral nervous system

B-II-11 ONCOLOGIC IMAGING

Content reviewed by ESOI (European Society of Oncologic Imaging)

INTRODUCTION

In Level II the trainee should, in addition to the knowledge, competencies and skills acquired in the first 3 years of training, have in-depth knowledge of the following:

- Oncogenic processes to understand the biological basis of cancer and the various therapies developed to combat it
- Imaging techniques used in oncological imaging including (but not limited to) CT, MRI, PET, US, and hybrid imaging
- Contrast agents, PET tracer technology and advanced imaging protocols

The trainee must be able to stage different types of tumours across an array of imaging modalities, to describe the principles of response assessment in cancer while appreciating the differences between the different response criteria, to appreciate the role of imaging in cancer screening and surveillance, to highlight the fundamentals of interventional oncology while appreciating the risks and safety methods of the procedures.

KNOWLEDGE

CANCER: BIOLOGY & TREATMENT

- To develop an understanding of oncogenesis, angiogenesis, lymphangiogenesis and metastatisation including genomics and proteomics
- To understand the principles of treatment including surgery, locoregional therapies, chemotherapy (including systemic and targeted therapies; adjuvant and neoadjuvant) bone marrow / stem cell transplantation, immunotherapy and radiotherapy (conventional, brachytherapy and stereotactic)
- To develop core knowledge of the biology of different tumour types, particularly the most common cancers: lung, breast, colorectal and prostate.
- To understand the treatment strategies of different tumour types, particularly the most common cancers: lung, breast, colorectal and prostate
- To describe the acute and chronic complications of oncologic treatment and their imaging features

IMAGING TECHNIQUES IN ONCOLOGIC IMAGING

- To describe indications and contraindications for the various imaging examinations in oncologic imaging for staging and response assessment
- To describe the most appropriate imaging examination for oncologic imaging according to the clinical problem: ultrasound, CT, MRI and hybrid techniques (PET/CT, PET/MRI, SPECT/CT)
- To understand the strengths and limitations of each imaging technique in oncologic imaging
- To understand the role of endocavitary / endoscopic US techniques for tumour characterisation and staging

- To recommend appropriate endocavitary / endoscopic US investigations
- To describe the best contrast material and its optimal use according to the imaging technique and the clinical problem in oncologic imaging
- To understand the relative costs of the various imaging examinations in oncologic imaging
- To know the radiation burden and risks of different investigations in oncologic imaging
- To describe techniques for post-processing images in view of obtaining reformat, MIP, MinIP, vessel analysis, 3D analysis, including endoluminal reconstructions, fusion images as well as acquisition and treatment of functional studies in oncologic imaging
- To have detailed knowledge of US, CT, MRI, nuclear medicine and hybrid imaging techniques PET/CT, PET/MRI, findings and pitfalls in diagnosis in those cancers frequently referred for imaging
- To have a basic understanding of radiotracers used in hybrid imaging in oncology
- To understand the indications for functional imaging techniques in oncologic imaging

PRINCIPLES OF ADVANCED IMAGING TECHNIQUES AND CONTRAST AGENTS IN ONCOLOGIC IMAGING

- To understand the role of PET/CT in oncologic imaging
- To know about the most important PET radio tracers with fluorine 18, gallium 68 or carbon 11 including FDG, DOTATATE/DOTATOC, DOPA, choline, PSMA, FLT, F-MISO, acetate
- To describe PET imaging protocols, methods of PET image analysis and data processing and possible pitfalls and limitations of this technique in oncologic imaging
- To understand the principles of advanced MRI techniques used in oncologic imaging including:
 - » Dynamic contrast-enhanced (DCE) MRI
 - » Diffusion-weighted imaging (DWI)
 - » Spectroscopy using ¹H, ³¹P, ¹³C
 - » Targeted contrast agents and fMRI (BOLD)
- To understand the principles of advanced CT techniques including dynamic contrast-enhanced CT (perfusion CT) and Dual-energy computed tomography (DECT) in oncologic imaging
- To understand the principles of contrast-enhanced ultrasound (CEUS) in oncologic imaging
- To describe the imaging protocols and methods of image analysis and data processing for the different MRI, CT and US techniques in oncologic imaging

CANCER STAGING

- To describe the imaging anatomy and the pathways of spread for the common cancer types
- To describe the common staging systems for common cancer types: current TNM and clinical staging classification and to know their limitations
- To describe the application of imaging techniques including US, CT, MRI, nuclear medicine and hybrid techniques PET/CT and PET/MRI for cancer staging
- To have an understanding of the appropriate choice of imaging techniques and/or the appropriate sequence of imaging techniques in the investigation of specific clinical problems in oncologic imaging
- To have an appreciation of common imaging 'false positives' and 'false negatives' in cancer staging and the role

of different imaging techniques for lesion characterisation

- To know the national and international guidelines for staging common cancer types
- To understand the principles of structured and criteria-based reporting

TREATMENT PLANNING IN ONCOLOGIC IMAGING

- To understand the role of imaging in treatment planning e.g., surgery, radiotherapy
- To have awareness of national and international guidelines in treatment planning in oncologic imaging

CANCER RESPONSE ASSESSMENT & CLINICAL TRIALS

- To describe the principles of response assessment to appreciate the advantage and limitations of the different response criteria e.g., RECIST, combined size and enhancement criteria, iRECIST, PET Deauville and PERCIST criteria
- To understand the concept of clinical trials, including main endpoints for evaluation of treatments like response rate, disease control rate, time to progression, disease-free and progression-free survival, best overall response
- To understand the concepts of baseline examination, nadir, tumour response, tumour progression, stable disease, target lesion, non-target lesions, new lesions, pseudoprogression, hyperprogression
- To understand the advantages and limitations of each imaging method for response evaluation (ultrasound, CT, MRI, nuclear medicine and PET/CT, PET/MRI)
- To understand the role of advanced techniques in response assessment: DCE-MRI, DW-MRI, MR-Spectroscopy, PET/CT, PET/MRI, Perfusion CT
- To understand the challenges of advanced imaging biomarker development in clinical trials: generalisability, standardisation, QA, QC
- To have awareness of national and international guidelines in cancer response assessment and clinical trials

CANCER SCREENING & SURVEILLANCE

- To understand the principles of screening and the organisation of screening using breast, lung and colorectal cancer as core examples and to have awareness of national and international guidelines in this field
- To appreciate the main advantages and drawbacks of a screening programme
- To describe the role for different imaging techniques in surveillance in different cancer types
- To describe the patterns of recurrence in common cancers
- To describe the role of imaging in assessing suspected disease recurrence and the advantages and limitations of different techniques
- To understand the potential of advanced techniques for surveillance: whole body MRI, PET/CT with different radiotracers

INTERVENTIONAL ONCOLOGY

- To describe the basic principles of safe interventional technique, the anatomy relevant to the procedure and the recognised complications of the procedures
- To be familiar with the available spectrum of interventional procedures used in oncological radiology

- To describe the common image-guided interventional oncologic procedures including percutaneous fine needle aspiration, biopsy or drainage and local tumour treatments
- To know the potential risks and complications of common procedures in interventional oncology
- To be aware of the pharmacological actions of the agents used in analgesia and sedation and the necessary monitoring required to perform this safely
- To describe the processes and actions required in intermediate life support and management of anaphylaxis

SKILLS

- To justify, protocol, conduct and supervise oncological imaging examinations to a high standard
- To confidently tailor examinations appropriately to the clinical question in oncologic imaging
- To confidently interpret all images relevant in the diagnosis, staging, assessment of response and detection of recurrent disease of the common cancers
- To develop resources to diagnose, stage and assess response of unusual tumour types using all imaging modalities
- To accurately assess response to treatment according to recognised objective response criteria in oncologic imaging
- To advise on the appropriate diagnostic imaging and follow-up protocols for different tumour types
- To plan effective imaging pathways for the common cancers
- To confidently discuss the appropriate imaging strategies in oncologic imaging with clinicians within a multidisciplinary setting
- To communicate effectively with patients and professional colleagues in the interdisciplinary oncological team
- To provide clinicians with optimised images which may aid surgical management or treatment planning including the role of imaging in radiotherapy planning and treatment
- To competently work with US, CT and MRI-guided interventions and, where appropriate, fluoroscopic imaging
- To undertake the following procedures under supervision: US-guided biopsy of masses and lymph nodes, CT-guided biopsy of masses (retroperitoneal, pelvic side-wall, thoracic and lymph nodes) and liver lesions, drainage of collections and local tumour treatments

COMPETENCES AND ATTITUDES

- To conduct good clinical care: To be aware of the limits of personal knowledge and to know when to seek further information or help
- To maintain good medical practice: To keep the knowledge base up to date and be able to discuss current medical practice with colleagues and patients
- To work in partnership with patients: To be aware of different levels of patient understanding and personality types, to explain diagnostic and therapeutic radiology procedures effectively, and to exhibit a flexible approach taking into account different learning styles and expectations of patients
- To demonstrate good team working skills: To understand the value of teamwork (multidisciplinary teams) and to demonstrate good communication with professional colleagues
- To assure and improve the quality of care: To be able to describe an effective clinical governance approach and to participate in clinical governance processes e.g., clinical audit, guidelines development
- To develop teaching competence: To understand the principles of teaching and learning, and conduct teaching sessions in a quality assured training programme and develop competence as a clinical supervisor

B-II-12 PAEDIATRIC RADIOLOGY

Content reviewed by ESPR (European Society of Paediatric Radiology)

INTRODUCTION

In Level II the trainee should, in addition to the knowledge, competencies and skills acquired in the first 3 years of training, have in-depth knowledge of the following:

- Normal anatomy, relevant embryology and common variants of the developing body systems on both pre - and postnatal imaging with all modalities
- Congenital malformations of all systems encountered in antenatal, neonatal life, during childhood and early adolescence
- Imaging features, causes, basic clinical features and complications of infectious and inflammatory diseases in antenatal and postnatal life until adolescence
- Imaging features, basic clinical features and complications of tumours and tumour treatment in childhood and adolescence
- Imaging findings in acute and chronic trauma including abusive trauma in the developing child
- Diseases and conditions that affect multiple systems in children

The trainee must be able to justify, plan and supervise imaging studies adopted for children.

KNOWLEDGE

- To have an in-depth understanding of developmental anatomy during childhood
- To describe normal variants in childhood that may mimic disease
- To have a basic understanding of embryology as applied to paediatric diseases
- To have a basic understanding of the various stages of embryonic and fetal development and their respective appearance on US and MRI
- To understand and describe the principles guiding the construction of a child-friendly environment
- To understand the ALARA principle and dose consideration and their application in paediatric patients
- To list and describe imaging guideline algorithms specific to children
- To have an in-depth knowledge of indications and contraindications for contrast media within the paediatric population including neonates
- To describe the standard procedure in emergency situations, including resuscitation techniques in children

BRAIN AND SPINE

- To describe the imaging features and basic clinical features of the main congenital malformations of the brain (for details, see B-II-9 Neuroradiology, Congenital and developmental abnormalities)
- To describe the imaging features, causes and basic clinical features of hydrocephalus in infants, children and adolescents
- To describe the imaging features, causes and basic clinical features of benign enlargement of subarachnoid spaces
- To describe the imaging features, causes and basic clinical features of subependymal and intraventricular haemorrhage in infants

- To describe the imaging features, causes and basic clinical features of white matter injury in preterm babies
- To have an in-depth knowledge of the imaging features and basic clinical features of elevated intracranial pressure in infants, children and adolescents
- To have an in-depth knowledge of the imaging features and basic clinical features of brain tumours in infants, children and adolescents
- To have an in-depth knowledge of the imaging features and basic clinical features of head trauma in infants, children and adolescents, including abusive head trauma
- To describe discriminating clinical and imaging features of abusive head trauma in infants, children and adolescents and recommendations for further imaging investigation
- To have an in-depth knowledge of the imaging features and basic clinical features of intracranial infections (including antenatal infections e.g., TORCHES group) in infants, children and adolescents
- To describe the imaging features, causes and basic clinical features of intracranial ischaemia / stroke in infants, children and adolescents
- To have an in-depth knowledge of the imaging features and basic clinical features of pituitary disease in infants, children and adolescents
- To describe the imaging features and basic clinical features of spinal malformations including closed and open spina dysraphism, dermal sinus, split cord malformations

HEAD AND NECK

- To describe the imaging features and basic clinical features of the main congenital malformations of the head and neck region including the orbit, the nose, the pharynx, the temporal bone and salivary gland in infants, children and adolescents
- To describe the imaging features, causes, basic clinical features and complications of inflammatory / infectious disorders of the head and neck region in infants, children and adolescents
- To have an in-depth knowledge of tumours of the head and neck region in infants, children and adolescents
- To have an in-depth knowledge of the imaging features and basic clinical features of traumatic lesions of the head and neck region in infants, children and adolescents
- To describe the imaging features of congenital and acquired thyroid diseases in infants, children and adolescents
- To appreciate the appearances and significance of fibromatosis colli

CHEST

- To describe the imaging features of normal thymus and its variants in infants, children and adolescents with all modalities
- To describe the imaging features of congenital abnormalities of tracheobronchial tree, lung and thorax (bronchopulmonary foregut malformation spectrum, bronchopulmonary sequestration, congenital pulmonary airway malformation, lobar emphysema, bronchial atresia, pulmonary venolobar (Scimitar) syndrome) in infants, children and adolescents, using all modalities
- To describe the radiographic imaging features of causes for neonatal respiratory distresses in premature and term babies and neonates
- To describe the radiographic imaging features of foreign body aspiration and ingestion in infants, children and adolescents
- To describe the radiographic imaging features of bronchiolitis in infants, children and adolescents

- To describe the imaging features of cystic fibrosis in infants, children and adolescents with all modalities
- To describe the imaging features and significance of acute and chronic or recurrent lower respiratory tract infection in infants, children and adolescents
- To describe the clinical, radiographic, US, CT and MRI imaging features of chest wall and pleural-based diseases including effusions in infants, children and adolescents
- To describe the clinical, radiographic and CT imaging features of trauma to the thorax including pneumothorax and other air leaks in infants, children and adolescents
- To describe the imaging features of infiltrative diseases of the lung in infants, children and adolescents
- To describe the imaging features of metastatic diseases to the lung in infants, children and adolescents
- To describe the imaging features of mediastinal masses (germ cell tumour, cystic mediastinal masses, lymphadenopathies, lymphoma, neurogenic tumours) in infants, children and adolescents
- To describe the imaging features of congenital diaphragmatic hernia, diaphragm palsy and eventration in infants, children and adolescents

CARDIOVASCULAR

- To be familiar with typical imaging appearances of cardiac anomalies on chest radiographs
- To have a basic understanding of paediatric cardiac MRI and CT, their difference and main indications
- To understand the imaging features and clinical features of the main congenital malformations of the cardiovascular system including aortic arch abnormalities, vascular rings and slings, tetralogy of Fallot and transposition of the great arteries in infants, children and adolescents
- To describe the imaging features, causes and basic clinical features of arterial hypertension in infants, children and adolescents
- To describe the imaging features, causes and basic clinical features of inflammatory / infectious disorders of the cardiovascular system in infants, children and adolescents
- To have an in-depth knowledge of the imaging features and basic clinical features of traumatic lesions of the cardiovascular system in infants, children and adolescents
- To understand the main pathologies of the coronary arteries in children
- To have an in-depth knowledge of the imaging features and basic clinical features of vascular malformations and vascular tumours in infants, children and adolescents

ABDOMEN

- To describe the clinical and radiographic imaging features of oesophageal atresia in neonates
- To describe the clinical and imaging features of necrotising enterocolitis and related gastrointestinal perforation in neonates
- To describe the imaging features and basic clinical features of ano-rectal malformations in neonates
- To describe the clinical and imaging features of hypertrophic pyloric stenosis in neonates and infants
- To describe the imaging features and basic clinical features of gastrointestinal obstruction in neonates
- To describe the clinical and imaging features and complications of Hirschsprung's disease in neonates, infants, children and adolescents
- To describe the imaging features and basic clinical features of gastro-oesophageal reflux in infants, children and adolescents
- To describe the imaging and clinical features of intestinal malrotations and volvulus in infants, children and

adolescents

- To have an in-depth knowledge of the imaging and clinical features, and treatment of intestinal intussusception in infants, children and adolescents
- To have an in-depth knowledge of the imaging and clinical features of appendicitis in infants, children and adolescents
- To describe the imaging and clinical features of peritonitis in neonates, infants, children and adolescents
- To describe the imaging and clinical features of inguinal hernia in infants, children and adolescents
- To describe the imaging and clinical features of inflammatory bowel diseases and the respective complications in infants, children and adolescents
- To describe the imaging and clinical features of blunt abdominal trauma in infants, children and adolescents, and related complications
- To describe the imaging and clinical features of ingested foreign bodies in infants, children and adolescents
- To describe the imaging features and basic clinical features of disorders of the hepatobiliary system (jaundice in infants, biliary atresia, choledochal cyst) in infants, children and adolescents
- To understand the principles of pre-and post-liver transplant as well as intraoperative liver transplant imaging
- To describe the imaging features and basic clinical features of disorders of portal circulation in infants, children and adolescents
- To understand the principles of the indications for cholangiography, biliary drainage and abscess drainage, in neonates, infants, children and adolescents
- To describe the basic clinical and imaging features and basic clinical features of disorders of the pancreas in infants, children and adolescents
- To describe the basic clinical and imaging features of disorders of the spleen in infants, children and adolescents
- To list main congenital anomalies of the kidney and urinary tract (CAKUT), ranging from vesicouretral reflux and pelviureteric junction obstruction to more complex malformations such as horseshoe kidney, ectopia, or fusion anomalies
- To describe the clinical and imaging features of lower urinary tract malformations in infants, children and adolescents
- To describe the imaging features and basic clinical features of urinary tract infection in infants, children and adolescents
- To appreciate the imaging features of the different grades of vesico-ureteral reflux and urethral anomalies on voiding cystourethrography with all modalities (fluoroscopy, scintigraphy, contrast-enhanced ultrasonography)
- To describe the imaging features and basic clinical features of dilation of the urinary tract in infants, children and adolescents
- To describe the imaging strategy, imaging features and basic clinical features of cystic diseases of the kidneys in infants, children and adolescents
- To describe the imaging features of urolithiasis and nephrocalcinosis in infants, children and adolescents
- To understand the principles of pre- and post-renal transplant imaging, as well as intraoperative renal transplant imaging
- To describe the indications for nephrostomy
- To describe the imaging features and basic clinical features of oncologic disorders of the abdomen in infants, children and adolescents, including neuroblastoma, Wilms tumours, hepatoblastoma, Burkitt's lymphoma,

with differential diagnosis

- To describe the imaging features and basic clinical features of common disorders of the adrenal glands in infants, children and adolescents
- To describe the imaging features and basic clinical features of sexual development disorders in neonates and infants
- To describe the imaging features and basic clinical features of pubertal development disorders in infants and adolescents
- To describe the imaging features and basic clinical features of common gynaecological disorders (malformations, ovarian cysts and tumours) in girls
- To describe the imaging features and basic clinical features of common disorders of the testis and scrotum in boys

MUSCULOSKELETAL

- To describe the imaging features and basic clinical features of fractures (accidental and non-accidental) in neonates, infants, children and adolescents
- To understand the medico-legal aspects of non-accidental injury
- To describe the imaging features and basic clinical features of accidental trauma and polytrauma in infants, children and adolescents
- To describe the imaging features and basic clinical features of common bone dysplasia (achondroplasia, osteogenesis imperfecta, congenital metabolic disorders) in children and adolescents
- To describe the imaging features and basic clinical features of infiltrative bone marrow diseases in infants, children and adolescents, including sickle cell disease and thalassaemia
- To have basic knowledge of the imaging features and clinical features of metabolic bone diseases including those of rickets
- To describe the imaging features and basic clinical features of bone tumours in children and adolescents
- To describe the imaging features, differential diagnosis and clinical significance of joint effusions in children and adolescents
- To describe the imaging features and basic clinical features of osteomyelitis and septic arthritis in children and adolescents
- To describe the imaging features and basic clinical features of juvenile rheumatoid arthritis and haemophilia in children and adolescents
- To describe the imaging features and basic clinical features of congenital disorders of the spine, including scoliosis (congenital and idiopathic) and dysraphism in infants, children and adolescents
- To describe the imaging features and basic clinical features of developmental dysplasia of the hip in neonates, infants, children and adolescents
- To describe the imaging features and basic clinical features of transient synovitis in children and adolescents
- To describe the imaging features and basic clinical features of Legg-Calvé-Perthes disease in children
- To describe the imaging features and basic clinical features of slipped capital femoral epiphysis in children
- To describe the imaging features and basic clinical features of congenital disorders of the ankle and foot, including congenital tarsal coalition
- To describe the imaging features and basic clinical features of osteochondrosis, including Schmorl's nodes and Scheuermann's disease, in children and adolescents

- To describe the imaging features and basic clinical features of soft tissue tumours in children and adolescents
- To describe the most common sports injuries in the growing skeleton

KNOWLEDGE OF ENTITIES AND CONDITIONS AFFECTING MULTIPLE SYSTEMS

- To describe the neuro-imaging features, extracranial manifestations, diagnostic criteria and clinical features of neurofibromatosis type I and type II
- To describe the neuro-imaging features, extracranial manifestations, diagnostic criteria and clinical features of tuberous sclerosis
- To describe the neuro-imaging features, extracranial manifestations, diagnostic criteria and clinical features of Sturge-Weber disease
- To describe the neuro-imaging features, extracranial manifestations, diagnostic criteria and clinical features of von Hippel-Lindau disease
- To describe the basic imaging features of less common neurocutaneous syndromes
- To describe the imaging features and clinical features of haematological disorders in children and adolescents
- To describe the imaging features and basic clinical features of Langerhans cell histiocytosis

SKILLS

- To perform ultrasound examinations in infants, children and adolescents and to appreciate the difference between basic and advanced ultrasound machines
- To choose the most suitable oral, intracavity or intravenous contrast material and its optimal use according to the imaging technique, the clinical problem and the age in paediatric radiology
- To observe and/or perform under supervision ultrasound of brain and spine in the infant
- To observe and/or perform under supervision Doppler sonography of the intracranial vessels in infants, children and adolescents
- To observe and/or perform under supervision ultrasound of the joints including the hip in neonates and infants
- To observe and/or perform under supervision ultrasound of the chest, abdomen and pelvis in neonates, infants, children and adolescents
- To observe and/or perform under supervision voiding cystourethrography in infants, children and adolescents
- To observe and/or perform under supervision contrast media studies of the gastrointestinal tract in infants, children and adolescents
- To confidently perform a treatment for intussusception
- To observe and/or perform interventional procedures like biopsies and drainages
- To confidently plan and supervise a CT examination in infants, children and adolescents and to tailor it to the individual situation and age, with a dose as low as reasonably achievable
- To confidently plan and supervise an MRI examination in infants, children and adolescents and to tailor it to the individual situation and age of the patient in regard to the potential use of intravenous contrast medium and spatial resolution
- To confidently perform proper post-processing tasks of examinations in paediatric radiology, including multiplanar reformations (MPR), maximum intensity projections (MIP), minimum intensity projections (MinIP)

and fusion images

- To understand nuclear imaging studies with gamma cameras, SPECT and PET/CT in children
- To describe the standard procedure in emergency situations, including resuscitation techniques in children
- To plan sedation and general anaesthesia in children and ensure adequate monitoring of patients during sedation or interventional procedures

COMPETENCES AND ATTITUDES

- To confidently justify diagnostic imaging examinations in infants, children and adolescents
- To confidently choose the best-suited method for evaluating disorders in infants, children and adolescents
- To communicate with the patient and parents / caretakers in order to obtain informed consent prior to diagnostic imaging and interventional procedures in infants, children and adolescents
- To confidently choose optimal imaging parameters for radiographic, ultrasonographic, CT and MRI examinations in infants, children and adolescents
- To confidently apply techniques to reduce exposure doses for radiographic and CT examinations in infants, children and adolescents
- To confidently design imaging protocols and standard operating procedures for CT examinations infants, children and adolescents, including the appropriate application of intravenous contrast, positioning, spatial and temporal resolution, with a special focus on dose reduction
- To confidently design imaging protocols and standard operating procedures for MRI examinations of the brain and spine, including the appropriate application of intravenous contrast, spatial and temporal resolution, and the potential use of sedation
- To supervise and teach technical staff to ensure that appropriate images of infants, children and adolescents are obtained
- To confidently judge the quality of imaging examinations in infants, children and adolescents and to devise strategies to improve image quality
- To confidently interpret and report radiographs, fluoroscopy tests, ultrasonographic examinations, CT studies and MRI examinations of infants, children and adolescents
- To report oncological studies in infants, children and adolescents according to international standards (RECIST, SIOPEN, WHO) applicable to the specific situation
- To appreciate own limitations and to identify when it is appropriate to obtain assistance in interpreting and reporting images of infants, children and adolescents
- To confidently identify urgent and/or unexpected findings in imaging examinations of infants, children and adolescents and to communicate these timely and properly
- To empathically communicate with patients and their parents / caretakers in order to explain their imaging findings
- To perform at multidisciplinary conferences and tumour boards for diseases of infants, children and adolescents including meetings discussing adverse events / discrepancies
- To have awareness about the availability of guidelines for justification and appropriateness of imaging in children, and how to make the best use of them

B-II-13 UROGENITAL RADIOLOGY

Content reviewed by ESUR (European Society of Urogenital Radiology)

INTRODUCTION

In Level II the trainee should, in addition to the knowledge, competencies and skills acquired in the first 3 years of training, have in-depth knowledge of the following:

- Normal anatomy and common variants of the kidneys, retroperitoneum, bladder as well as male reproductive system
- Different disease entities affecting the kidneys, retroperitoneum, bladder as well as male reproductive system

The trainee must be able to confidently justify and choose the appropriate examination technique that is needed for the patient in question, adapted to the clinical situation.

The trainee must be show evidence of a development of practical skills to perform specialist diagnostic imaging examinations and interventional procedures.

KNOWLEDGE

NORMAL ANATOMY AND VARIANTS

- To describe the normal anatomy of the retroperitoneal spaces and pathways
- To describe the triple obliquity of the kidney
- To list the criteria of normality of the pyelocaliceal system on CT urography
- To describe normal variants, including junctional parenchymal defect, column of Bertin's hypertrophy, foetal lobulation or lipomatosis of the sinus and to accurately differentiate these variants from disease
- To describe the anatomy of the bladder wall
- To describe the segments of the male urethra and the location of the urethral glands
- To understand the physiology of micturition
- To describe the zonal anatomy of the prostate
- To describe the imaging features of prostatic zonal anatomy with ultrasound and MRI
- To describe the ultrasound anatomy of scrotal structures (testicular and extratesticular)
- To describe the Doppler anatomy of the testicular and extratesticular vessels

RENAL PHYSIOLOGY AND KINETICS OF CONTRAST AGENTS

- To describe the physiology of renal excretion of contrast agents
- To describe enhancement curves within renal compartments after intravascular injection of contrast agents
- To define the potential nephrotoxicity of contrast media and to list risk factors of contrast induced nephrotoxicity
- To list methods to reduce the risk of contrast nephrotoxicity

- To list measures to reduce the risk of contrast media nephrotoxicity
- To have an understanding of nephrogenic systemic fibrosis (NSF) including the definition of NSF, the clinical features and the risk factors
- To describe the appropriate use of Gadolinium-based contrast media in patients at risk

CONGENITAL

- To list main renal malformations, such as ectopia, duplications or fusions
- To describe congenital malformations of the bladder and urethra
- To describe congenital malformations of the prostate, seminal vesicles, vas and the testes

ADRENAL GLANDS

- To describe the imaging and clinical features of adrenal insufficiency
- To describe the imaging features and basic clinical features of benign solid tumours of the adrenal glands
- To describe the imaging features and basic clinical features of adrenal cysts
- To describe the imaging features and basic clinical features of malignant tumours of the adrenal gland in the adult and in the paediatric population
- To describe the management and principles of differential diagnosis of incidentally discovered lesions of the adrenal glands
- To describe the imaging features and basic clinical features of adrenal trauma

KIDNEY AND URETER

- To describe the imaging features of vascular disorders of the kidney
- To describe the imaging features and basic clinical features of medical nephropathies
- To describe the imaging features and basic clinical features of infections of the kidney and/or urinary tract
- To describe the imaging features of cystic diseases of the kidney
- To describe the imaging features and basic clinical features of kidney tumours
- To describe staging of kidney tumours, with specific focus on imaging impact
- To describe the imaging features of calculi of the urinary tract
- To describe the imaging features and basic clinical features of urinary obstruction
- To describe the imaging features and basic clinical features of ureteral tumours
- To describe the imaging features after renal transplantation
- To describe the imaging features and basic clinical features of trauma to the kidneys and/or ureters
- To describe the principles of CT urography including the main indications, choice of technique, choice of contrast agent and dose

BLADDER AND URETHRA

- To describe the imaging features and basic clinical features of inflammatory disorders of the bladder
- To describe the imaging features and basic clinical features of bladder tumours
- To describe staging of bladder tumours, with specific focus on imaging impact
- To describe the imaging features of urinary diversion
- To describe the imaging features and basic clinical features of urinary outflow obstructions

- To describe the imaging features and basic clinical features of incontinence and functional disorders of the bladder
- To describe the imaging features and basic clinical features of strictures of the urethra
- To describe the imaging features and basic clinical features of urethral diverticula
- To describe the imaging features and basic clinical features of trauma to the bladder and urethra
- To describe the principles of cystourethrography including the main indications, choice of technique, choice of contrast agent, dose, film timing and indications

MALE REPRODUCTIVE SYSTEM

- To describe the imaging features and basic clinical features of inflammatory disorders of the prostate
- To describe the imaging features and basic clinical features of benign prostatic hyperplasia
- To describe the imaging features and basic clinical features of prostate cancer
- To describe prostate cancer staging, with specific focus on imaging impact
- To describe the imaging features and basic clinical features of inflammatory disorders of the testes
- To describe the imaging features and basic clinical features of tumoural pathology of the testes
- To describe the imaging features and basic clinical features of testicular torsion
- To describe the imaging features and basic clinical features of Peyronie's disease
- To describe the various imaging manifestations of impotence
- To describe the imaging features and basic clinical features of priapism
- To describe the imaging features and basic clinical features of tumoural pathology of the penis
- To describe the imaging features and basic clinical features of traumatic lesions of the penis

SKILLS

- To choose and/or guide the choice of the most appropriate imaging examination according in urogenital radiology related to the clinical problem and the patient's history, including any previous radiological examinations
- To choose the most suitable contrast material and its optimal dose and use according to the imaging technique, the clinical problem, and relevant patient related criteria in urogenital radiology
- To identify patients at risk of contrast nephrotoxicity
- To take measures to reduce the risk of contrast nephrotoxicity
- To take measures to reduce the risk of contrast media nephrotoxicity
- To identify patients at risk to develop NSF
- To confidently perform ultrasound examinations of the kidneys, urinary tract and of the male reproductive system
- To perform Doppler spectrum analysis on intrarenal vessels (for resistive/pulsatility index measurement) and on the entire course of the proximal renal arteries for velocity calculation
- To confidently perform cystourethrography
- To confidently plan a CT examination in urogenital radiology and to tailor it to the individual situation with a dose as low as reasonably achievable
- To confidently perform state-of-the-art CT urography
- To confidently plan an MRI examination in urogenital radiology and to tailor it to the individual patient in regard to spatial resolution and the potential use of intravenous contrast medium
- To observe and/or perform under supervision image-guided biopsies, e.g., renal parenchymal biopsies, biopsies of kidney masses, and biopsies of retroperitoneal masses

- To observe and/or perform under supervision image-guided drainage procedures related to the urogenital tract
- To observe and/or perform under supervision percutaneous nephrostomy
- To confidently perform proper post-processing tasks of examinations in urogenital radiology, including multi-planar reformations (MPR), maximum intensity projections (MIP), minimum intensity projections (MinIP) and fusion images for diagnostic purposes and for imaging-guided interventional procedures and therapies

COMPETENCES AND ATTITUDES

- To confidently justify diagnostic imaging examinations in urogenital radiology
- To confidently choose or guide the best-suited method for evaluating disorders in urogenital radiology
- To communicate with the patient in order to obtain informed consent prior to diagnostic imaging studies and interventional procedures in urogenital radiology
- To confidently choose optimal imaging parameters for radiographic, ultrasonographic, CT and MR examinations in urogenital radiology
- To confidently apply techniques to reduce radiation exposure doses for radiographic and CT examinations in urogenital radiology
- To confidently design imaging protocols and standard operating procedures for CT examinations in urogenital radiology, including the appropriate application of intravenous contrast, positioning, spatial and temporal resolution, with a special focus on dose reduction
- To confidently design imaging protocols and standard operating procedures for MR examinations in urogenital radiology, including the appropriate application of intravenous contrast and of spatial and temporal resolution
- To confidently design imaging protocols for prostate MR examinations according to PI-RADS v2.1 recommendations
- To supervise and teach technical staff to ensure that appropriate images of the urogenital system are obtained, adjusted to the clinical problem
- To confidently judge the quality of imaging examinations in urogenital radiology and to provide strategies to improve image quality
- To confidently interpret and report radiographs, ultrasonographic examinations, CT studies and MRI examinations in urogenital radiology
- To report oncological studies in urogenital radiology according to international standards (RECIST, WHO) applicable to the specific situation
- To report prostate MRI according to PI-RADS v2.1 algorithm
- To appreciate one's own limitations and to identify when it is appropriate to obtain an additional opinion (-s) in performing, interpreting and reporting images of the urogenital system
- To confidently identify urgent and/or unexpected findings in imaging examinations of the urogenital system and to communicate these findings timely and properly with the referring physician or his replacer responsible for patient care
- To empathically communicate with patients and their families in order to explain their imaging findings of the urogenital system, whenever appropriate
- To actively contribute at multidisciplinary meetings and tumour boards for diseases of the urogenital system

B-II-14 MEDICAL IMAGING INFORMATICS

Content reviewed by EuSoMII (European Society of Medical Imaging Informatics)

INTRODUCTION

In Level II the trainee should, in addition to the knowledge, competencies and skills acquired in the first 3 years of training, have in-depth knowledge of the following:

- Different aspects of computer science and information technology in the field of medical imaging

This Level II curriculum is the basis for further training in this domain (if desired) to obtain a specialisation in Medical Imaging Informatics.

Knowledge, skills, competences and attitudes obtained are broad and applicable in any radiology specialisation.

KNOWLEDGE

KNOWLEDGE OF RADIOLOGY WORKSTATIONS, NETWORKS, RIS, PACS AND EPR

- To have knowledge about data storage systems: online vs. offline, RAID, cloud storage
- To understand the principles, advantages and risks of future directions of image storage and processing (e.g., web and cloud-based archiving and processing)
- To know about vendor neutral archiving
- To know ergonomics and ideal conditions of a radiological reading room, including the effects of ambient light and background noise
- To understand the value and functioning of auxiliary thin-client solutions that radiologists may interact with in browser-based computing
- To have basic knowledge of emergency and disaster plans (both disaster recovery and business continuity) concerning the Imaging Informatics environment and specifically the PACS and RIS

KNOWLEDGE OF STANDARDS AND CODES

- To know specific features of DICOM, HL7 and IHE (such as modality worklist function and task creation)
- To have a basic knowledge of interoperability of medical devices and medical information systems
- To learn about image formats typically used in research, such as NIFTI and Analyze

KNOWLEDGE OF RADIOLOGICAL SOFTWARE APPLICATIONS

- To understand the functioning and application of image processing and analysis, radiomics, quantitative imaging biomarkers, image fusion, virtual endoscopy, virtual reality, augmented reality and functional analysis
- To know the techniques and applications of advanced image (post-) processing techniques (such as ADC, IVIM, measurements, DTI, spectroscopy, perfusion and PKM imaging, BOLD flow)
- To know the differences between thin-client applications and real workstations
- To know the role of tablets and mobile devices for image distribution in and out of radiology department
- To have knowledge of digital radiation exposure monitoring systems (REM)
- To understand the SSDE (size-specific dose estimate), a newer radiation dose index for CT
- To have a working knowledge about Structured Reporting (SR) coding (RadLex)
- To know about report template repositories
- To have knowledge of safe and secure use of social networks with knowledge of privacy issues
- To have knowledge of Hospital Information System (HIS) and Electronic Medical Record (EMR) ontology and terminology
- To have knowledge of web-portals application for Radiology
- To know how to use an online patient portal to provide patients with information about the results and images of radiological examinations
- To have knowledge of teleradiology requirements
- To know the role of Imaging Informatics in using key performance indicators and dashboards
- To have a basic knowledge of Computer Aided Detection (CAD) systems and to understand the difference between CADe and CADx
- To have knowledge on the different technical options to implement AI and deep learning applications in the radiology workflow
- To know the general principles of imaging biomarkers and radiomics applications

KNOWLEDGE RELATED TO MANAGEMENT, LEGISLATION AND COMMUNICATION

- To know about the rules and regulations applicable to Imaging Informatics, both on a national and EU-based level, such as GDPR (General Data Protection Rules)
- To know and understand the terminology related to Imaging Informatics, both from a technical and medical point of view

SKILLS

- To be able to use workstations to obtain useful quantitative imaging results
- To be able to incorporate quantitative imaging results into structured reports
- To be able to use the information of radiation dose registration systems to reduce radiation dose to patients while maintaining optimal image quality
- To be able to use dosimetry to optimise scanning protocols and quality management
- To participate in a shared workflow

COMPETENCES AND ATTITUDES

- To be able to use IT to improve efficiency and quality of care
- To know how to use IT for proactive communications with peers, clinicians and patients
- To be an advocate of and a driving force behind Medical Imaging Informatics projects
- To be able to evaluate commercial informatics tools in Radiology for commissioning purposes

2. ORGANISATION OF TRAINING

A. SCHEDULE AND LENGTH OF TRAINING

The revised European Training Curriculum for Radiology continues to outline a five-year (three + two) training period, consisting of Level I Training over the first three years followed by a more flexible Level II Training with potential special interest (elective) rotations during the last two years.

LEVEL I TRAINING: YEARS 1-3

During the first three years of training, the fundamentals of undertaking and interpreting a wide range of imaging techniques and disease manifestations remain the essential curriculum component.

A detailed knowledge of normal imaging anatomy and physiology should be gained in the early stages of training. Early in this three-year period, trainees should acquire the necessary knowledge of basic sciences, the physical basis of image formation in all imaging techniques, picture archiving and communication systems (PACS), radiology and hospital information systems, quality control and quality management, radiation physics, radiation biology, radiation protection, anatomy, physiology, cell biology and molecular structure, biochemistry and techniques related to radiological procedures. Knowledge must also be gained of the pharmacology and application of contrast media and the treatment of adverse reactions to them. A basic understanding of computer science needs also to be acquired. The fundamentals of clinical research, statistics and evidence-based medicine as applied to radiology should be taught as well; ideally, there should be exposure to active radiological research with the option to perform own scientific projects. Moreover, the trainee should become familiar with a wide range of radiological skills including the performance of a variety of procedures.

Radiology is a clinical specialty, and while the extent of direct clinical exposure will vary from country to country, the European Training Curriculum for Radiology promotes the concept that good extra-radiological clinical competence is an essential component of radiology training. This experience is required to allow the radiologist to provide a safe medical environment for patients within the Radiology Department and during image-guided interventions. Moreover, training should ascertain that the reporting of diagnostic imaging will have a clinically relevant and patient-focused emphasis.

Experience in Emergency Radiology is an integral component of radiology training and must be accommodated during Level I Training – ideally at the very beginning of training – as to provide the necessary knowledge, skills, competences and attitudes within the training programme. The identification and communication of urgent and unexpected findings should already be trained at this point in time. The role of the radiologist as a communicator with patients and families and as a collaborator with other clinical specialists should moreover be emphasised.

Multidisciplinary and clinico-radiology conferencing, including the conduction of tumour boards for various organ systems, has become an integral component of medical care and decision-making.

Frequently, such conferencing is conducted under the chairmanship of a radiologist and within a radiology department, emphasising the importance of training and direct experience of such meetings within the modern radiology curriculum. During Level I Training, participation in multidisciplinary conferences and tumour boards should be encouraged and such conferences may be conducted by the trainee under supervision.

A written or electronic logbook of activity during Level I Training should be maintained. This should provide a formal validated record of competences achieved and examinations performed and should form an integral part of regular assessments of satisfactory training.

The following fields of radiology should be taught during Level I Training and are outlined in the European Training Curriculum for Radiology:

B-I-1 Breast Radiology

B-I-2 Cardiac and Vascular Radiology

B-I-3 Chest Radiology

B-I-4 Emergency Radiology

B-I-5 Gastrointestinal and Abdominal Radiology

B-I-6 Gynaecological and Obstetric Radiology

B-I-7 Head and Neck Radiology

B-I-8 Interventional Radiology

B-I-9 Musculoskeletal Radiology

B-I-10 Neuroradiology

B-I-11 Paediatric Radiology

B-I-12 Urogenital Radiology

B-I-13 Nuclear medicine as basic training

B-I-14 Radiation Protection Education and Training

B-I-15 Principles of Imaging Technology & Molecular Imaging

B-I-16 Principles of Medical Imaging Informatics

B-I-17 Communication and Management

B-I-18 Research and Evidence-Based Medicine

A three-month rotation in nuclear medicine facilities equipped with conventional and hybrid imaging equipment (PET/CT and SPECT/CT scanner) scanner should be available during basic training, either in the home department or in an adjacent or offsite nuclear medicine teaching department in order to become familiar with basic methods in this specialty.

LEVEL II TRAINING: YEARS 4-5

The European Training Curriculum for Radiology recognises that most European radiologists now work in teams, where individual members will have specific skills and competences. This increasing training in specific areas of interest is encouraged, while it is recognised that general competences should be maintained also by subspecialised radiologists and that general radiologists are needed as well. The European Society of Radiology emphasises that during the fourth and fifth years a developing knowledge in general radiology should continue to be nourished. Elective interest training during this period may apply to two areas of interest, while training in the other areas of radiology should continue as well. For interested trainees, options to actively perform radiological research projects should ideally be offered.

A written or electronic logbook of activity during Level II Training should be maintained. This should provide a formal validated record of competences achieved and examinations performed and should form an integral part of regular assessments of satisfactory training. Level II Training by no means substitutes Level III Training.

The following fields of radiology are outlined in the Level 2 section of the European Training Curriculum for Radiology:

B-II-1 Breast Radiology

B-II-2 Cardiac and Vascular Radiology

B-II-3 Chest Radiology

B-II-4 Emergency Radiology

B-II-5 Gastrointestinal and Abdominal Radiology

B-II-6 Gynaecological and Obstetric Radiology

B-II-7 Head and Neck Radiology

B-II-8 Interventional Radiology

B-II-9 Musculoskeletal Radiology

B-II-10 Neuroradiology

B-II-11 Oncologic Imaging

B-II-12 Paediatric Radiology

B-II-13 Urogenital Radiology

B-II-14 Medical Imaging Informatics

The recommendations of the European Training Curriculum are not an end in themselves, but should be interpreted in the context of understanding the seamless transition from training to lifelong continuous medical education (CME) and continuous professional development (CPD). An appreciation of this continuum should be instilled at an early stage of training already.

LEVEL III TRAINING: BEYOND YEAR 5

Level III Training is a formal, full-immersion training in a radiological subspecialty after the completion of radiology (Level I and Level II) training. Parts of Level II Training in a subspecialty may be counted for subspecialisation. However, full subspecialisation always requires further Level III (subspecialty) Training beyond Level I and Level II Trainings. Level III Training curricula are beyond the scope of the present document.

B. CURRICULUM OF TRAINING / INFRASTRUCTURAL ASPECTS

The specialty of radiology involves all aspects of medical imaging that provide information about morphology, function, cell activity and those aspects of interventional radiology or minimally invasive therapy (MIT) that fall under the remit of the radiology department.

TRAINING MODULES

Trainees should participate in clinical radiology examinations and activities whose extent and complexity should gradually increase in line with experience. It is important that trainees systematically rotate through all sections of the radiology department at an early stage to become conversant with the principles of the main techniques and to gain a working knowledge of all relevant imaging methods.

The precise structure of the system-based modules will vary from country to country and from department to department, but the time balance should reflect the importance of the system to the core of radiological practice.

Training should be under the direction and supervision of the radiology department of a large teaching hospital, although models for clinic- and academy-based training also exist. Each training programme should outline the educational goals and objectives of the programme with respect to knowledge, skills, competences and other attributes of trainees at each level of training and for each major training task.

Most radiology training should be acquired at a single teaching institution where all or most subspecialty disciplines are available. However, several institutions can pool their resources in order to provide complete access to all techniques and specialties. Ideally, this department should be affiliated to a university and should have full and close collaboration with a medical physics department. The availability of a 24-hours Emergency Department is recommended. Ready access to university anatomy, biochemistry, statistics, physics and pathology departments should be available to all training centres. If at all possible, in-house physics training should be available. Teaching principles should include didactic lectures, tutorials etc., but there should also be a large component of one-to-one apprenticeship relations with the staff faculty.

The spectrum of patient and investigative material available during training should be sufficient to enable the trainee to gain experience in all fields of radiology. When possible, training should ideally be integrated into a single department; however, attendees of an institution with limited specialties may be required to ensure comprehensive training elsewhere.

Within each teaching department, a local tutor or mentor with direct responsibility for in-house training should be appointed to ensure that an appropriate proportion of service versus training time be maintained.

Regular assessments should be carried out on a yearly basis and easy access for trainees to local coordinators should be encouraged.

The trainee should be involved in the radiological examination and diagnosis of patients presenting in the emergency department and should be able to appropriately evaluate patients who are severely or critically ill. It is not anticipated that a trainee would enter into an emergency on-call rotation entailing clinical responsibility until the end of the first year of training. An objective evaluation (examination) should take place at the end of the first year and satisfactory performance should be a prerequisite for unsupervised emergency room and/or supervised on-call duties. Competence in dealing with acute medical emergencies arising within the radiology department should be ensured.

All reporting should be supervised and all radiology reports should be discussed and validated with the trainee by an experienced staff radiologist.

Patient safety specifically with reference to radiological practice should be thoroughly emphasised. Such safe radiology practice should include validation of any request for radiological examination with respect to risk factors, exposure to ionising radiation and possible alternatives employing non-ionising radiation.

The fully trained radiologist should be capable of working independently when solving most common clinical problems and those undertaking interventional procedures should also have sufficient clinical background knowledge to accept direct referrals and to clinically manage patients in the immediate time frame surrounding such interventions.

EQUIPMENT

Only departments with adequate imaging equipment and services should be approved for training. The equipment should comply with radiological safety standards and should be in good technical condition. Technical efficiency, security, radiation safety and controls should be of an adequate standard and conform to agreed national quality control criteria. Radiation protection should be organised and radiation should be monitored according to European standards. The down-time of the equipment for maintenance and repair should be minimal and should not interfere with training.

The techniques for adequate radiological training will depend on local availability, but should include the following:

Conventional radiography (including fluoroscopy)

Mammography

Ultrasound

Computed tomography

Digital subtraction angiography

Interventional radiology

Magnetic resonance imaging

Access to nuclear medicine with hybrid imaging equipment

READING FACILITIES AND TEACHING MATERIALS

Access to quiet reading areas with internet portals should be available to trainees within the department. Audio-visual equipment and rooms should be available in the radiology department, sufficient to enable the implementation of the teaching programme. An adequate supply of teaching materials should include textbooks and journals (either in print edition or in an online version). Teaching facilities should include access to online medical publications, teaching aids (including Education on Demand, EURORAD etc.) and a full radiology library. A wide range of e-learning facilities have now been developed within ESR and are available on the website. Active in-house development of a teaching file represents a very valuable stimulus for trainees and is encouraged.

COURSE PARTICIPATION

Attendance at outside courses and scientific congresses / meetings will depend on the stage of training and the relevance of the courses to the trainee's stage of training. Throughout the five years,

attendance at a minimum of two relevant international and five national congresses or courses is encouraged. Presentation of original research by the trainees at these scientific meetings should be encouraged. Such participation should be logged and recorded on an annual basis. A spirit of academic excellence should be fostered within the department, including a pride in profiling the department's achievement at local, national and international scientific gatherings, and in presenting scientific results in renowned, peer-reviewed national and international journals. Authorship of research publications and peer-reviewed journals should be encouraged and ongoing mentoring in this area should be made available by more senior academic staff. PhD programmes offer an excellent tool to train residents in radiology in scientific work and are expected to play a greater role in research training in radiology in the future throughout Europe.

Advice on research principles and protocols is freely available to ESOR members through the Research Committee of the ESR.

PROPORTION OF RADIOLOGICAL TRAINING IN UNIVERSITY, TEACHING, NON-UNIVERSITY AND/OR PRIVATE INSTITUTIONS

Rotations through small and subspecialised hospitals may frequently supplement basic radiological training and are to be recommended for limited periods. Ready access to university level physics and pathology departments should exist for all training centres. Ideally, in-house physics training should be available.

All the university departments and training hospitals should be part of a coordinated national or federal training scheme. Training schemes should ideally be subject to single national organisations to standardise the educational experience and maximise efficiencies.

EUROPEAN SCHOOL OF RADIOLOGY

The European School of Radiology (ESOR) offers complementary and continuing education to residents and young radiologists through visiting schools, visiting seminars, scholarships, exchange programmes for fellowships, and tutorials, thus enhancing and ensuring the further development of young radiologists during their training.

The ESR Education Committee encourages young radiologists to participate in the programmes and to benefit from internationally renowned faculties and/or training in pre-selected, highly esteemed reference training centres in Europe and beyond (see <http://www.myesr.org>).

C. ASSESSMENT AND EVALUATION

Assessment is defined as the process by which information is obtained in relation to known objectives or goals with a further subdivision into formative and summative assessments. Evaluation is defined as the process designed to provide information that aids in judging a given situation.

Formal trainee appraisal and assessment should take place at regular intervals (at least once a year). In order to verify that appropriate modular training has been obtained, this assessment should include appraisal of the logbook referred to above. Assessments should also cover clinical and technical competences, including interpersonal skills and suitability as a clinically active doctor. As part of the assessment process, trainees should be given an opportunity to provide their own observations on training facilities and teaching personnel on a confidential basis.

On completion of the training period the radiologist is expected to be capable of working independently and unsupervised in a hospital or outpatient facility.

At the end of training, objective measurement of an achieved standard should be made depending on national custom and practice.

A European Board of Radiology (EBR)-coordinated European Diploma in Radiology (EDiR) and EDiR Training Evaluation is available to supplement these national evaluations.

D. GOVERNANCE

ACCREDITATION OF TRAINING DEPARTMENTS

Accreditation of training departments by a competent and independent authority coordinated through either the national society or a national authority with responsibility for training should be performed.

It is recommended that accreditation should be carried out every five years and should include the following:

Number and type of radiological examinations (the spectrum of patient and investigative material available should be sufficient to enable the trainee to gain adequate experience for full radiological training)

Number, type and standard of imaging equipment

Trainee access to the full range of imaging techniques

Adequacy of trainer–trainee ratios

Teaching programmes available

Teaching materials

Research activity of trainees and of the department in general

The European Training Assessment Programme (ETAP) 2.0 provides assessment and certification of radiology training programmes and departments. It is a joint project of the European Board of Radiology (EBR) and the UEMS Radiology section and is available to all institutions from countries of the ESR Institutional and Associate Institutional Member Societies. ETAP provides a high quality and objective assessment, and the subsequent certification based on the assessment results: Silver, Gold or Platinum.

RELATIONSHIP OF TRAINING PROGRAMME WITH REGULATORY AUTHORITIES

This will vary greatly throughout Europe, but it is of importance that the central regulatory authorities cooperate and that easy cross-referencing takes place among the bodies responsible for radiological education and licensing regulatory authorities, teaching centres, local hospital administrations etc. Adequate educational funding budgets should be ring-fenced within health care structures.

E. ENTRUSTABLE PROFESSIONAL ACTIVITIES

WHAT ARE ENTRUSTABLE PROFESSIONAL ACTIVITIES?

The adoption of competency-based education (CBE) in the medical field training signifies a paradigm shift from traditional knowledge-based education that complements substance knowledge with generic competencies.

Entrustable professional activity (EPA) assessments have emerged as a crucial component in this transition, working in conjunction with conventional resident assessments such as logbooks and summative examinations. EPAs aim to augment substantive knowledge with additional medical competencies, providing a more comprehensive evaluation of the confidence level in resident performance. Essentially, EPAs denote specific tasks or processes delegated to residents once they have demonstrated adequate competence. The term “entrustment” in EPAs reflects the confidence level a supervisor or educator has in a resident’s ability to independently perform a specific task, with the level of entrustment increasing as competence improves.

The fundamental concepts of EPAs involve assessing the process rather than the individual performing the task. Successful completion of the EPA enables both the resident and the instructor to provide organised and constructive feedback.

EPAs focus on integral tasks in medical practice, often linked to real-world clinical scenarios. They require a combination of knowledge, skills, and professional attitudes. Currently, the European Training Curriculum separates competencies into Knowledge, Skills, and Competencies and Attitudes, but considers EPAs only as competencies in the current form.

Deitte et al. (2016) laid out ten generic EPAs for radiology applicable across various subspecialty scenarios [1]:

1. Collaborates as a member of an interprofessional team
2. Triage/protocols exams
3. Interprets exams and prioritises a differential diagnosis
4. Communicates results of exams
5. Recommends appropriate next steps
6. Obtains informed consent and performs procedures
7. Manages patients after imaging and procedures
8. Formulates clinical questions and retrieves evidence to advance patient care
9. Behaves professionally
10. Identifies system failures and contributes to a culture of safety and improvement

These generic EPAs facilitate the assessment of resident’s capabilities in diverse real-world scenarios, fostering a comprehensive approach to medical training.

As medical education evolves, the integration and refinement of EPAs within existing competency-based frameworks hold promise for better preparing future healthcare professionals for the challenges of contemporary medical practice [2]. EPAs can be adapted to various medical specialties and subspecialties, providing a flexible framework tailored to specific clinical scenarios.

In the field of radiology, examples of EPAs encompass collaborating as an interprofessional team member, triaging and protocoling exams, interpreting imaging studies and prioritising a differential diagnosis, effective communication of results, recommending appropriate next steps, obtaining informed consent and performing procedures, managing patients post-imaging, formulating clinical questions, exhibiting professional behaviour, and identifying system failures to contribute to a culture of safety and improvement [3-5].

A survey from the European Society of Radiology (2023) showed that EPAs are gradually finding application in radiology resident training programs throughout Europe, with anticipation of increased. There is a favorable outlook regarding the adoption of EPAs in radiology, as well as a positive attitude towards establishing a unified European framework [2].

WHY USE EPAs

EPAs in medical education offer several benefits, emphasising guided feedback that contributes to ongoing professional development. This feedback enables residents to set goals, track progress, and continuously refine their skills.

EPAs provide a framework for holistic assessment, allowing educators to evaluate a resident's ability to integrate knowledge, skills, and attitudes in real-world clinical scenarios.

EPAs also contribute to quality assurance in medical education by establishing clear competence standards, ensuring that residents achieve predefined benchmarks for independent practice.

FOR WHOM TO USE EPAs

EPAs represent units of professional work that can be entrusted to a trainee once they demonstrate adequate competence [6]. These tasks or sets of tasks, essential to healthcare and linked to patient care, vary from simple to complex, each designed to be reliably observable and measurable [7]. Primary beneficiaries of EPAs are trainees in medical education programs, at both undergraduate and postgraduate levels. EPAs provide a structured pathway for learners to progressively develop and demonstrate competence in various professional activities essential to their role [6].

EPAs can be utilised in training programs to assess the competence and progress of trainees. They help determine when a trainee is ready to take on certain clinical tasks independently and when they may still require supervision.

WHEN TO USE EPAs

EPAs play a vital role at different stages of medical education and practice, integrating theoretical learning with practical skills. In undergraduate education, EPAs introduce students to clinical competencies, evolving through graduate and postgraduate training to assess readiness for independent practice [8]. For practicing professionals, EPAs are crucial in maintaining skills, particularly with new technologies or procedures. They are especially useful during hands-on clinical rotations to demonstrate competence in real-world scenarios, in assessment meetings where educators evaluate trainee progress, and in professional development programs where practicing clinicians update their skills in response to medical advancements. EPAs facilitate curriculum development, integrating practical skills into theoretical learning, ensuring a comprehensive educational experience, preparing students for actual clinical challenges. They also promote interprofessional education, crucial in a multidisciplinary healthcare environment [9].

In radiology education, EPAs bridge the gap between theoretical concepts and practical interpretation of imaging. These structured tasks assigned to radiology residents align with typical responsibilities in radiology, encompassing activities like interpreting diverse imaging modalities, performing ultrasound-guided procedures, and engaging in patient consultations. This hands-on exposure empowers residents to apply their theoretical knowledge in real-world scenarios, thereby refining their diagnostic and procedural skills.

Moreover, EPAs serve as an evaluative framework for educators to assess the progress of radiology residents during meetings, by focusing towards assessing the resident's capacity to independently interpret images, communicate findings effectively to other healthcare professionals, and manage radiology services within a clinical context [1].

Beyond this, EPAs ensure that the curriculum covers essential aspects such as radiation safety, patient care, and ethical use of imaging technologies. EPAs involving multidisciplinary teamwork (e.g., collaborating on complex cases or participating in tumour boards) enhance collaborative and communication skills, essential in a healthcare setting [10].

HOW TO USE EPAs IN RADIOLOGY

EPAs are employed at various points in medical education and training to assess learners' capabilities, provide targeted feedback, and guide their progression toward independent practice. The specific timing of EPA use depends on the educational context, program structure, and the desired outcomes for learners.

The flexibility and adaptability of EPAs in radiology allows for tailoring to meet departmental needs, ensuring that residents understand the context and implications of their work. This approach not only ensures the development of technical proficiency but also cultivates well-rounded professionals capable of navigating the complexities of modern healthcare environments upon completing their residency.

The EPA concept allows to make competency-based decisions on the level of supervision required. In general, there are five levels of supervision defined (e.g. levels by ten Cate [7]):

Level 1 - Observation but no execution, even with direct supervision

Level 2 - Execution with direct, proactive supervision

Level 3 - Execution with reactive supervision, on request and quickly available

Level 4 - Supervision at a distance and/or post hoc

Level 5 - Supervision provided by the trainee to more junior colleagues

For example, a radiology resident may be assigned the EPA of interpreting a standard chest X-ray. Initially, direct supervision is required, with the resident interpreting the X-ray under the physical presence of an experienced radiologist. As the residents' competence advances, the level of supervision may transition to indirect reactive supervision, where the supervisor is available upon request but not physically present [11].

Furthermore, residents can progress to interpreting more complex imaging, such as CT or MRI scans, or engaging in interventional procedures under varying levels of supervision, based on their demonstrated competencies.

EPAs in radiology extend beyond image interpretation and encompass activities like communicating critical findings to clinicians, participating in multidisciplinary team meetings, or conducting research and presenting findings. Assessment through EPAs is well-suited for these tasks, as they require a combination of medical knowledge, technical skill, and professional behaviour [1].

The inclusion of various activities in EPAs ensures a comprehensive assessment of a resident's capabilities beyond the core skill of image interpretation.

EXAMPLES OF EPAs IN RADIOLOGY, IN THE THREE MAIN DOMAINS

EXAMPLE OF AN EPA FOR A DIAGNOSTIC EXAMINATION, E.G. READING A CHEST CT

Examination of a Patient Using Chest CT

Description

Timeframe: This activity includes the activities associated with a chest CT in chronological order: from receiving the request to completion, i.e., written communication/possibly oral communication with the referring physician.

Setting: Emergency and elective

Including:

1. Main components:

- Handling of information including information systems
- Indication review/protocol/visitation
- (Image acquisition), handling of postprocessing tools, AI
- Interpretation (anatomical/physiological knowledge, structural search patterns)
- Assessment, differential diagnosis
- Reporting (written communication)
- For emergency patients: oral communication Communication/interdisciplinary discussion
- Interprofessional Communication (Technician)

2. Occasionally:

- Communication with Patients

Exclusive: e.g. Evaluation of Coronary Vessels

Possible Risks

- Radiological Misinterpretation leads to Misdiagnosis or Treatment Delay
- Health Hazard for the Patient if history is not considered (known allergy, renal failure)
- Misinterpretations lead to loss of trust among clinicians

Domains of Competence

Medical Expert

Communicator

Professional

Collaborator

Knowledge, Skills, Attitude

For the activity to be entrusted, based on the above-mentioned components: A patient

Knowledge:

- is proficient in handling the requirements (information & question) provided by the clinically active colleagues
- is proficient in handling the information contained in information systems
- has knowledge of the mentioned clinical suspected diagnosis and relevant differential diagnoses,

alternative examination methods, as well as examination risks (high-dose X-ray, anaphylaxis, nephrotoxicity, hyperthyroidism, pregnancy, etc.)

- is able to use the available software (post-processing tools, AI, etc.)
- is familiar with thoracic radiological anatomy and has physiological knowledge (e.g. ventilation and perfusion of the lungs)
- is familiar with differential diagnoses and applies them correctly

Skills

- has a structured search pattern in image analysis
- creates a structured report
- provides a correct assessment that is useful to the clinical colleague (where appropriate, also with procedure suggestion)
- can provide a time-critical and concise oral assessment of the examination to the clinical colleague
- supports the colleague in an advisory capacity (e.g. additional examination where necessary)

Professional Attitude:

- adequately supports the MTRA team in performing a demanding examination (e.g. TIC in CT pulmonary embolism)
- is able to engage in conversation with patients, if desired, and provide them with appropriate orientation (usually involves procedural rather than substantive information, e.g. informing them about the time frame for transmitting the report to the general practitioner)
- Works effectively with referring physicians
- Works effectively with other professional groups
- Demonstrates an empathetic, open, and receptive attitude towards patients and their relatives
- Demonstrates "A-RICH" behaviour (Accountability, Reliability, Integrity, Capability, Humility)
- Recognises own limitations and asks for help when needed

Assessment methods

- Direct observation
- Case-based discussion / Entrustment-based Discussion
- Report review

Expectations regarding the achievement of a certain level of independence

After 1 year: indirect supervision (level 3)

After 3 years: remote supervision (level 4)

EXAMPLE OF AN EPA FOR A PROCEDURE, E.G. BREAST BIOPSY

Ultrasound-Guided (Breast) Biopsy

Description

Time Frame: This activity includes all tasks associated with a diagnostic ultrasound-guided (breast) biopsy in chronological order, from receiving the request to the discharge of the patient and communication with the referrer.

Setting: Elective, possibly emergency.

Including:

1. Main Components:

- Handling of information including information systems.
- Review of indications/protocoling/visitation.
- Informed consent of the patient.
- Planning & execution of the procedure including measures for risk minimisation.
- Wound care and discharge of the patient.
- Preservation and transfer of orders to pathology (including suspected diagnosis/differential diagnosis).
- Reporting/interdisciplinary discussion.

2. Excluding:

- therapeutic breast biopsy (VAB).

Possible Risks

- Induction of complications.
- Mistreatments, delays in treatment.
- Loss of trust and reputation damage among patients and referring colleagues.

Competency Domains

Medical Expert

Communicator

Professional

Collaborator

Knowledge, Skills, Attitude

For the task to be entrusted, based on the above components: A junior doctor

Knowledge:

- Can make or verify the indication for performing a biopsy.
- Has knowledge of the suspected diagnosis and relevant differential diagnoses.
- Knows alternative examination and biopsy methods.
- Conducts a risk-benefit assessment.
- Conducts an urgency analysis.
- Knows the sonoanatomy of the respective body region.
- Knows the applications as well as advantages and disadvantages of different biopsy devices and tools.
- Knows the indications, contraindications, and risks of analgesics (especially local anesthetics) and anxiolytics (especially short-acting benzodiazepines).
- Knows possible complications (bleeding risk, anaphylaxis) and checks for contributory historical factors or contraindications.
- Masters the handling of histological examination results and the radiological-pathological result correlation.

Skills:

- Masters handling the request made by the clinically active colleague (information & order placement) including handling the information contained in information systems.
- Masters the diagnostic method "sonography."
- Correctly applies biopsy devices and tools.
- Masters the technical process including risk minimisation measures:
 - Positioning of the patient.
 - Sitting position of the operator.
 - Sterile working environment.
 - Choice and preparation of the biopsy device and tools.
 - Execution of analgesia (usually local anesthesia).
 - Navigation of the biopsy device.
 - Application of biopsy markers.
 - Image documentation (2-plane documentation).
 - Preservation of samples.
 - Wound care.
- Creates a helpful follow-up order to pathology including suspected diagnosis and differential diagnosis.
- Creates a structured report.

- Provides a correct, useful assessment to the clinically active colleague (where indicated, also with a procedure proposal).
- Can convey a time-critical and concise oral assessment of the examination to the clinically active colleague (including in cases of complications).
- Supports the colleague with advice where indicated (e.g., additional examination where necessary).

Professional Attitude:

- Shows an empathetic, open, and receptive attitude towards patients and their relatives.
- Informs patients as barrier-free as possible and in the sense of “shared decision-making”:
- Recapitulation of history.
- Indication.
- Technical process.
- Advantages/disadvantages/risks/consequences; possibly alternatives.
- Postinterventional impairments.
- Result transmission to the referrer.
- If appropriate, adequate outlining of further procedures.
- Assesses the judgment capacity of the patient (e.g., in minors).
- Works effectively with referring physicians.
- Works effectively with other professional groups.
- Shows “A-RICH” behaviour (Accountability, Reliability, Integrity, Capability, Humility).
- Recognises own limits and asks for help if needed.

Assessment Methods:

- Direct observation.
- Case-based discussion / Entrustment-based discussion.
- Assessment of image and report documentation (chart review).

Expectations Regarding Achieving a Certain Level of Independence

After 2 years: indirect supervision (Level 3)

After 5 years: remote supervision (Level 4)

EXAMPLE OF AN EPA ON COLLABORATION AND COMMUNICATION E.G. LEADING RADIOLOGIST DURING MULTIDISCIPLINARY MEETING

Hosting a Multidisciplinary Meeting as a Radiologist

Description

The resident is able to prepare and successfully lead a multidisciplinary meeting as a radiologist

Definition and limitations

This EPA can be done in any teaching hospital where multidisciplinary meetings are being held.

Possible Risks

The resident may misinterpret or miscommunicate findings, which may lead to false diagnoses and/or inappropriate patient management

Domains of Competence

Medical Expert

Communicator

Professional

Collaborator

Leader

Knowledge, Skills, Attitude

Knowledge:

- Required knowledge and skills for image interpretation
- Ability to evaluate the reliability of previous diagnoses and imaging interpretations, as well as potential sources of error
- Ability to recommend complementary imaging as required)

Professionalism:

- Ability to work efficiently as part of a multidisciplinary team, understand the responsibility of the radiologist in the diagnostic workup, and the relationship to the management responsibility of the referring physician
- Time management in preparing the meeting

Communication and collaboration:

- Ability to present the relevant findings, their conclusions, and differential considerations in a concise and understandable manner
- Ability to answer questions while understanding the limits of own knowledge and understanding, ability to follow up on questions that require more consideration

Leadership skills:

- The resident is able to serve as the leader of the meeting while managing his/her time ensuring an efficient flow of the meeting

Personal competence and management of knowledge:

- Ability to prepare case presentations, obtain relevant information from the medical records, and choose the appropriate imaging results from presentation
- Ability to independently acquire more information if needed
- Consult a colleague before the meeting if needed

Self-evaluation:

- The resident is able to evaluate and, when necessary, correct his/her own performance

Assessment methods

- Evaluation of the performance of the radiology resident hosting at least one (several if necessary) multidisciplinary meeting(s)
- Discussion with feedback, self-evaluation
- If necessary, feedback can be sought from other persons who attended the meeting

When to perform

This EPA can be performed at any stage of the residency, depending on the working environment

References

1. Deitte LA, Gordon LL, Zimmerman RD et al (2016) Entrustable Professional Activities: Ten Things Radiologists Do. *Acad Radiol* 23:374-381. doi: 10.1016/j.acra.2015.11.010
2. European Society of Radiology (ESR) (2023) Resident education in radiology in Europe including entrustable professional activities: results of an ESR survey. *Insights Imaging* 14:139. doi: 10.1186/s13244-023-01489-4
3. Ten Cate O (2005). Entrustability of professional activities and competency-based training. *Med Educ.* 39:1176-1177. doi: 10.1111/j.1365-2929.2005.02341.x
4. Ten Cate O, Schumacher DJ (2022) Entrustable professional activities versus competencies and skills: Exploring why different concepts are often conflated. *Adv Health Sci Educ* 27:491-499. doi: 10.1007/s10459-022-10098-7
5. Brown DR, Moeller JJ, Grbic D et al (2022) Core Entrustable Professional Activities for Entering Residency Pilot. Entrustment Decision Making in the Core Entrustable Professional Activities: Results of a Multi-Institutional Study. *Acad Med* 97:536-543. doi: 10.1097/ACM.0000000000004242
6. Ten Cate O, Taylor DR (2021) The recommended description of an entrustable professional activity: AMEE Guide No. 140. *Med Teach* 43:1106-1114. doi: 10.1080/0142159X.2020.1838465
7. Ten Cate O (2013) Nuts and bolts of entrustable professional activities. *J Grad Med Educ* 5:157-158. doi: 10.4300/JGME-D-12-00380.1
8. Ten Cate O, Chen HC, Hoff RG et al (2015) Curriculum development for the workplace using Entrustable Professional Activities (EPAs): AMEE Guide No. 99. *Med Teach.* 37:983-1002. doi: 10.3109/0142159X.2015.1060308
9. Ten Cate O, Pool IA (2020) The viability of interprofessional entrustable professional activities. *Adv Health Sci Educ Theory Pract* 25:1255-1262. doi: 10.1007/s10459-019-09950-0
10. Lee SY, Sharma N, Kagoma YK et al (2022) Which Aspects of the CanMEDS Competencies are Most Valued in Radiologists? Perspectives of Trainees From Other Specialties. *Can Assoc Radiol J* 73:30-37. doi: 10.1177/08465371211008649
11. Peters H, Holzhausen Y, Boscardin C et al (2017) Twelve tips for the implementation of EPAs for assessment and entrustment decisions. *Med Teach* 39:802-807. doi: 10.1080/0142159X.2017.1331031

II. TRAINING REQUIREMENTS FOR TRAINERS

1. PROCESS FOR RECOGNITION AS TRAINER

All trainers shall be board-certified radiologists holding a nationally recognised qualification as a radiologist. Moreover, they should have teaching experience both in regard to undergraduate and post-graduate teaching.

Within each teaching department, a local tutor or mentor with direct responsibility for in-house training should be appointed to ensure that an appropriate proportion of service versus training time be maintained.

The number of qualified radiologists with teaching functions in the department should be sufficient to fulfil all the needs of teaching in each major subspecialty area and in general radiology. The expertise of the teaching staff should cover a broad spectrum and include the subspecialties as outlined in the detailed curriculum for the initial structured common programme. If necessary, departmental support should be given for modular training outside the base hospital.

Teaching staff should be motivated and ideally several should be pursuing a university-based academic career pathway. In-house teaching should include didactic lectures, small tutorial groups and one-to-one apprenticeship experience. The teachers should ideally attend teacher-targeted training courses and should be fully integrated into the overall university educational process. Where examinations are a feature of training all teachers should experience the appropriate practical examinations and participate as examiners.

2. QUALITY MANAGEMENT FOR TRAINERS

An active quality management program training for the trainer and training program should be instituted at all teaching centres.

This should include regular audits as well as feedback systems between the trainers and the trainees. It needs to be ascertained at regular intervals that the standards for education in radiology are met by the trainers.

Educational courses on pedagogical concepts, teaching methods and quality management should be attended at regular intervals.

III. TRAINING REQUIREMENTS FOR TRAINING INSTITUTIONS

1. PROCESS FOR RECOGNITION AS TRAINING CENTER

A. REQUIREMENTS ON STAFF AND CLINICAL ACTIVITIES

Training should be under the direction and supervision of the radiology department of a large teaching hospital, although models for clinic- and academy-based training also exist. Each training programme should outline the educational goals and objectives of the programme with respect to knowledge, skills, competences and other attributes of trainees at each level of training and for each major training task.

Most radiology training should be acquired at a single teaching institution where all or most sub-specialty disciplines are available. However, several institutions can pool their resources in order to provide complete access to all techniques and specialties. Ideally, this department should be affiliated to a university and should have full and close collaboration with a medical physics department. The availability of a 24-hour Emergency Department is recommended. Ready access to university anatomy, biochemistry, statistics, physics and pathology departments should be available to all training centres. If at all possible, in-house physics training should be available. Teaching principles should include didactic lectures, tutorials etc., but there should also be a large component of one-to-one apprenticeship relations with the staff faculty.

The spectrum of patient and investigative material available during training should be sufficient to enable the trainee to gain experience in all fields of radiology. When possible, training should ideally be integrated into a single department; however, attendees of an institution with limited specialties may be required to ensure comprehensive training elsewhere.

The number of qualified radiologists with teaching functions in the department should be sufficient to fulfil all the needs of teaching in each major subspecialty area and in general radiology. The expertise of the teaching staff should cover a broad spectrum and include the subspecialties as outlined in the detailed curriculum for the initial structured common programme. If necessary, departmental support should be given for modular training outside the base hospital.

Teaching staff should be motivated and ideally several should be pursuing a university-based academic career pathway. In-house teaching should include didactic lectures, small tutorial groups and one-to-one apprenticeship experience. The teachers should ideally attend teacher-targeted training courses and should be fully integrated into the overall university educational process. Where examinations are a feature of training all teachers should experience the appropriate practical examinations and participate as examiners.

A spirit of academic excellence should be fostered within the department, including a pride in pro-filing the department's achievement at local, national and international scientific gatherings, and in presenting scientific results in renowned, peer-reviewed national and international journals. Authorship of research publications and peer-reviewed journals should be encouraged and ongoing mentoring in this area should be made available by more senior academic staff. PhD programmes offer an excellent tool to train residents in radiology in scientific work and are expected to play a greater role in research training in radiology in the future throughout Europe.

B. REQUIREMENTS ON EQUIPMENT AND ACCOMMODATION

Only departments with adequate imaging equipment and services should be approved for training. The equipment should comply with radiological safety standards and should be in good technical condition. Technical efficiency, security, radiation safety and controls should be of an adequate standard and conform to agreed national quality control criteria. Radiation protection should be organised and radiation should be monitored according to European standards. The down-time of the equipment for maintenance and repair should be minimal and should not interfere with training.

The techniques for adequate radiological training will depend on local availability, but should include the following:

Conventional radiography (including fluoroscopy)

Mammography

Ultrasound

Computed tomography

Digital subtraction angiography

Interventional radiology

Magnetic resonance imaging

Access to nuclear medicine

Access to quiet reading areas with internet portals should be available to trainees within the department. Audio-visual equipment and rooms should be available in the radiology department, sufficient to enable the implementation of the teaching programme. An adequate supply of teaching materials should include textbooks and journals (either in print edition or in an online version). Teaching facilities should include access to online medical publications, teaching aids (including EURORAD etc.) and a full radiology library. A wide range of e-learning facilities have now been developed within ESR and are available on the website. Active in-house development of a teaching file represents a very valuable stimulus for trainees and is encouraged.

2. QUALITY MANAGEMENT WITHIN TRAINING INSTITUTIONS

An active quality management program should be instituted in all training institutions. This should include continuous improvement processes via a plan-do-check-act cycle, regular internal and external audits and continuous educational endeavours.

Accreditation of training departments by a competent and independent authority coordinated through either the national society or a national authority with responsibility for training should be performed.

It is recommended that accreditation should be carried out every five years and should include the following:

Number and type of radiological examinations (the spectrum of patient and investigative material available should be sufficient to enable the trainee to gain adequate experience for full radiological training)

Number, type and standard of imaging equipment

Trainee access to the full range of imaging techniques

Adequacy of trainer–trainee ratios

Teaching programmes available

Teaching materials

Research activity of trainees and of the department in general

Manpower planning

Clinical governance

The European Training Assessment Programme (ETAP) 2.0 provides assessment and certification of radiology training programmes and departments. It is a joint project of the European Board of Radiology (EBR) and the UEMS Radiology section and is available to all institutions from countries of the ESR Institutional and Associate Institutional Member Societies. ETAP provides a high quality and objective assessment, and the subsequent certification based on the assessment results: Silver, Gold or Platinum.

Coordination: ESR Office, Am Gestade 1, 1010 Vienna, Austria
Phone: +43 1 533 40 64-28 | Fax: +43 1 533 40 64-448
E-mail: boardaffairs@myesr.org | www.myESR.org
All data as per date: March 2024
ESR accepts no responsibility for errors or misprints

WWW.MYESR.ORG/TRAININGCURRICULUM

EUROPEAN TRAINING CURRICULUM FOR RADIOLOGY